



**LIVE**  
**2018**

# Leading Innovative Vascular Education

Organized by:




**Institute  
of Vascular Diseases (IVD),  
Greece**

In collaboration with:



**Hellenic Society of Vascular  
and Endovascular Surgery**



**STONY BROOK  
UNIVERSITY  
MEDICAL CENTER**

**Stony Brook University  
Medical Center, New York, USA**



**International Symposium  
on Endovascular Therapeutics**



**Intervention Master Aortic Course**



**May 24-26  
2018**

**Conference and Cultural Center  
of the University of Patras  
Patras, GREECE**

<http://www.live2018.gr>

**Abstract Book  
Oral & E-Poster Presentations**

---

**Abstract Book**

Patras, Greece, May 24-26, 2018  
LIVE 2018 - Leading Innovative Vascular Education

*Abstracts are published under all authors' acceptance to be included in all official symposium publications/  
material. ©All rights reserved.*

## Contents

<b>Organization</b> .....	4
<b>Oral Presentations</b> .....	5-26
<b>E-Poster Presentations</b> .....	27-56
<b>Index of Authors</b> .....	57-60



## Organization

### Organized by



**Institute of Vascular Diseases,  
(I.V.D.), Greece**

### In collaboration with:



**Hellenic Society  
of Vascular and Endovascular Surgery**



**Stony Brook University Medical Center,  
New York, USA**



**International Symposium  
on Endovascular Therapeutics**



**Intervention Master Aortic Course**

## LIVE 2018 Directors

### **Athanasios Giannoukas**

*Professor of Vascular Surgery,  
Faculty of Medicine, School of Health Sciences, University of Thessaly, Larissa, Greece*

### **Nicos Labropoulos**

*Professor of Surgery and Radiology, Director, Vascular Laboratory,  
Department of Surgery, Stony Brook University Medical Center, Stony Brook, New York, USA*

### **Miltos Lazarides**

*Professor of Vascular Surgery,  
Faculty of Medicine, School of Health Sciences, Democritus University of Thrace, Alexandroupolis, Greece*

### **Miltos Matsagkas**

*Professor of Vascular Surgery,  
Faculty of Medicine, School of Health Sciences, University of Thessaly, Larissa, Greece*

### **Dimitrios Tsetis**

*Professor of Interventional Radiology,  
Faculty of Medicine, School of Health Sciences, University of Crete, Heraklion, Greece*

### **Ioannis Tsolakis**

*Professor of Vascular Surgery,  
School of Medicine, University of Patras, Patras, Greece*

# Oral Presentations

OP1

**LARGE DIAMETER (>29 MM) PROXIMAL AORTIC NECKS ARE ASSOCIATED WITH INCREASED COMPLICATION RATES AFTER ENDOVASCULAR AORTIC ANEURYSM REPAIR**

**Petroula Nana<sup>1</sup>, Georgios Kouvelos<sup>1</sup>, Konstantinos Spanos<sup>2</sup>, Stylianos Koutsias<sup>2</sup>, Athanasios Giannoukas<sup>2</sup>, Miltiadis Matsagkas<sup>1</sup>**

<sup>1</sup>*Department of Vascular Surgery, Faculty of Medicine, School of Health Sciences, University of Thessaly, Larissa and University of Ioannina, Ioannina, Greece*

<sup>2</sup>*Department of Vascular Surgery, Faculty of Medicine, School of Health Sciences, University of Thessaly, Larissa, Greece*

**Aim:** To investigate the impact of proximal aortic neck diameter on outcome after EVAR of infrarenal abdominal aortic aneurysms.

**Methods:** 732 patients treated with EVAR, in two university centers, entered a case-control (1:1) retrospective analysis of prospectively collected data. Patients with a neck diameter of 29-32 mm (study group) were compared with patients with a neck diameter of 26-29 mm (control group) matched for age, gender, and maximum sac diameter. Patients treated outside the IFU of each endograft or with inadequate follow-up were excluded. Primary end-point was any neck-related adverse event (a composite of type Ia endoleak, neck-related secondary intervention, endograft migration) during follow-up.

**Results:** 64 patients with a proximal neck diameter of 29-32mm (study group) were compared with a matched control group with a neck diameter of 26-29mm (control group). Oversizing was significantly higher in the study group (p=0.001). Overall median available follow-up was 24 months (range 12-84 months). Primary end-point was recorded in 8 patients (12.5%) of the study and in 1 patient (1.6%) of the control group. Freedom from the primary endpoint at 36 months (SE <10%) was 87.3% for the study vs. 98.4% for the control group (log rank=4.66, p=0.03). On multiple regression analysis, the presence of a proximal neck >29mm was the only independent risk factor for neck related adverse events (OR 7.4; 95% CI 1.2-47.1).

**Conclusion:** EVAR in the presence of a wide proximal neck is likely to be associated with higher adverse neck-related event rates. In such cases, closer follow-up may be required.

OP2

**ENDOASCULAR REPAIR AND RE-ROOTING OF THE AORTIC ARCH VESSELS FOR TREATING AORTIC ARCH PATHOLOGIES: IS IT EFFECTIVE IN THE LONG TERM?**

**Fotis Eforakopoulos<sup>1</sup>, Christine Kalogeropoulou<sup>2</sup>, Efstratios Koletsis<sup>1</sup>, Christos Prokakis<sup>1</sup>, Nikolaos Charoulis<sup>1</sup>, Athina Sambalioti<sup>3</sup>, Charalambos Stroubos<sup>1</sup>, Panagiotis Papadopoulos<sup>1</sup>, Panagiotis Alexopoulos<sup>1</sup>, Emanouil Margaritis<sup>1</sup>, Fotini Fligou<sup>3</sup>, Dimitrios Dougenis<sup>1,4</sup>**

*<sup>1</sup>Departments of Cardiothoracic Surgery Patras' University School of Medicine, Patras, Greece*

*<sup>2</sup>Department of Radiology, Patras Medical School, Patras, Greece*

*<sup>3</sup>Department of Anesthesiology and intensive care, Patras University, Patras, Greece*

*<sup>4</sup>Department of Cardiac Surgery, Athens University School of Medicine, Attikon University Hospital, Athens, Greece*

**Background:** Thoracic endovascular aortic repair (TEVAR) is a widely used procedure that has drastically changed the management of thoracic aortic diseases. Nevertheless, there is limited information regarding the long term efficacy and results of TEVAR in patients treated with Endovascular repair and re-rooting of aortic arch vessels (AAR) for aortic arch pathologies.

**Methods:** Between 12/2005 and 4/2017, 54 patients underwent 61 TEVAR procedures using Gore/53 or Jotec/1 endografts. Among them, there were 14 pts (10M, 4F, mean age 67.3), who required AAR for degenerative aneurysms/7, post traumatic pseudoaneurysms/3, acute dissection/3 and penetrating atherosclerotic ulcer/1, which had resulted in a aorto-esophageal fistula. Landing zones were Z0/3, Z1/5, Z2/6. Spinal fluid drainage was electively used in 3. AAR procedures performed were: Atypical/3 typical/1 Bavaria Type A, carotid-carotid bypass/4, carotid-subclavian/8. For stent introduction the femoral artery/5, iliac/3, lower thoracic aorta/1 via open mini thoracotomy and the ascending aorta/5 were used.

**Results:** In the early postoperative period, there were no deaths, no strokes or leaks and no spinal cord ischemia. However, there was a right hemiplegia, resolved after aorto-left carotid bypass, a temporal left hand ischemia and a case with acute dissection required reintervention. In the long term and in a mean F/U of 4.9 years, there were no deaths or other events apart from one patient who had presented with aorto-esophageal fistula and died 1.5 years after surgery. One required a reintervention for persistent leak. Regarding AAR procedures, there were no pseudoaneurysm or other anastomotic events

**Conclusion:** Hybrid stenting of the aortic arch combined with AAR is a safe treatment modality especially in elderly and compromised patients. In the long term, endoleaks, brain and spinal cord as well as anastomotic complications are acceptable.

OP3

**EXPERIMENTAL ANIMAL STUDY OF A NOVEL DRUG-COATED BALLOON USING 3.5 MG/MM<sup>2</sup> PACLITAXEL COATING ON A CELLULOSE-BASED EXCIPIENT**

**George Lampropoulos<sup>1</sup>, Panagiotis M. Kitrou<sup>2</sup>, Konstantinos N. Katsanos<sup>2</sup>,  
Panagiotis N. Papadimitos<sup>2</sup>, Michail Theofanis<sup>2</sup>, Maria Vaiou<sup>3</sup>,  
Fotis Anagnostopoulos<sup>2</sup>, George Karpetas<sup>4</sup>, P. Kallidonis<sup>5</sup>, Stavros Spiliopoulos<sup>6</sup>,  
Anargyros Moulas<sup>3</sup>, Dimitrios Karnabatidis<sup>2</sup>**

<sup>1</sup>*Vascular Surgery Dpt., Patras University Hospital, Patras, Greece*

<sup>2</sup>*Interventional Radiology Dpt., University Hospital Of Patras, Greece*

<sup>3</sup>*Laboratory Of Chemistry And Biochemistry, Tei Of Thessaly, Larisa, Greece*

<sup>4</sup>*Department Of Anaesthesiology, University Hospital Of Patras, Greece*

<sup>5</sup>*Department Of Urology, University Hospital Of Patras, Greece*

<sup>6</sup>*2<sup>nd</sup> Department Of Radiology, Interventional Radiology Division,  
Attikon University Hospital, Athens, Greece*

**Purpose:** This was a two-stage experimental animal study investigating the safety and effectiveness (experiment A) together with the pharmacokinetic properties (experiment B) of a novel Drug-Coated Balloon (DCBn) using a 3.5µg/mm<sup>2</sup> paclitaxel coating on a cellulose-based excipient.

**Material and methods:** In experiment A, DCBn was compared with a control non-DCB and two different DCBs available in the market. The arterial system of swine was used (12swine, 6vessels in each animal; 72treatment sites in total). Randomization was performed in a 3:1:1:1 proportion (Group DCBn: 36balloons, Group non-DCB: 12balloons, Group market-DCB<sub>1</sub>: 12balloons, Group market-DCB<sub>2</sub>: 12balloons). Optical coherence tomography was performed immediately after balloon dilatation and at 3months. Primary endpoint was cross-sectional vessel wall area difference between baseline and 3 months. In experiment B, 38rabbits were used to assess DCBn's pharmacokinetic properties. Two vessels were used in every animal (76treatment sites). DCBn and market-DCB<sub>1</sub> were used in 18 animals and 20 animals had only DCBn. Animals were euthanized at 1hour, 24hours, 7days and 28days and vascular tissue was removed. Paclitaxel tissue concentration was determined by high-performance liquid chromatography/tandem mass spectrometry.

**Results:** Paired median differences over baseline were -0.09mm<sup>2</sup> for DCBn(p=0.33), +0.52mm<sup>2</sup> for Group non-DCB(p=0.04), +0.32mm<sup>2</sup> for GroupDCB<sub>1</sub>(p=0.14) and +0.32mm<sup>2</sup> (p=0.33) for Group DCB<sub>2</sub>. Paclitaxel was detectable at a concentration of 0.10±0.18ng/mg of tissue at 28days.

**Conclusion:** In this experimental study, the use of this novel DCB in both animal models was safe. Additionally, a significantly less cross-sectional vessel wall area difference was observed compared to non-DCB. Paclitaxel was detectable in the vascular tissue at 28 days.



OP4

**EVALUATION OF PERCUTANEOUS TRANSLUMINAL ANGIOPLASTY OUTCOME IN PATIENTS WITH CRITICAL LIMB ISCHEMIA, USING VOLUMETRIC CT PERFUSION TECHNIQUE: A FEASIBILITY STUDY**

**Nikolaos Galanakis<sup>1</sup>, Thomas G Maris<sup>2</sup>, Nikolaos Kontopodis<sup>3</sup>, Elias Kehagias<sup>1</sup>,  
Christos V Ioannou<sup>3</sup>, Nikolas Matthaïou<sup>1</sup>, Nikolaos Kosidekakis<sup>1</sup>,  
Konstantinos Perisinakis<sup>2</sup>, Apostolos Karantanas<sup>1</sup>, Dimitrios Tsetis<sup>1</sup>**

*<sup>1</sup>Department of Medical Imaging, University Hospital Heraklion,  
University of Crete Medical School, Heraklion, Greece*

*<sup>2</sup>Department of Medical Physics, University Hospital Heraklion, University of Crete Medical School, Heraklion, Greece*

*<sup>3</sup>Vascular Surgery Unit, Department of Cardiothoracic and Vascular Surgery, University Hospital Heraklion,  
University of Crete Medical School, Heraklion, Greece*

**Background-Aim:** To evaluate foot hypoperfusion in patients with critical limb ischemia (CLI) using quantitative perfusion multidetector-row computed tomography (MDCT) and estimate perfusion parameters changes before and after percutaneous transluminal angioplasty (PTA).

**Methods:** Thirteen patients (10 male, median age 72 years, range 51-84 years) with CLI [Rutherford 4 (n=1), Rutherford 5 (n=8), Rutherford 6 (n=4)] were investigated. They underwent CT foot perfusion (CTFP) examinations, using a 128-slice dual-energy CT scanner, 1 day before and 1 week after PTA. Key parameters such as permeability surface (PS), blood volume (BV) and blood flow (BF) were analyzed and applied for statistical comparison. The studies were also examined by a second observer to determine inter-observer reproducibility.

**Results:** Revascularization was technically successful in all patients and the ankle brachial index (ABI) increased from  $0.36 \pm 0.16$  to  $0.75 \pm 0.22$ . After revascularization, mean BV increased from  $1.43 \pm 0.83$  to  $4.13 \pm 1.53$  ml/100g, BF increased from  $15.19 \pm 4.97$  to  $31.27 \pm 7.86$  ml/100g/min and PS increased from  $2.7 \pm 1.95$  to  $7.38 \pm 3.85$  ml/min//100g,  $p < 0.05$ . All measurements demonstrated very good inter-observer reproducibility and ICC was 0.91 (95% CI 0.64-0.97) for BV, 0.94 (95% CI 0.83-0.98) for BF, and 0.95 (95% CI 0.86-0.98) for PS. The mean effective dose of the examination was estimated to be 0.29 mSv.

**Conclusions:** CTFP examination may be a reproducible and useful modality for the diagnosis of foot hypoperfusion and estimation of PTA outcome. Significant restitution of perfusion parameters was observed after successful revascularization.

OP5

**USE OF DRUG-COATED BALLOONS IN DYSFUNCTIONAL ARTERIO-VEINUS ACCESS TREATMENT.  
THE EFFECT OF CONSECUTIVE TREATMENTS IN TARGET LESION PRIMARY PATENCY**

**Ioannis Spyridonidis<sup>1</sup>, Panagiotis Kitrou<sup>1</sup>, Konstantinos Katsanos<sup>1</sup>,  
Panagiotis Papadimitos<sup>1</sup>, Michail Theofanis<sup>1</sup>, Maria Karahaliou<sup>1</sup>,  
Evangelos Papachristou<sup>2</sup>, Dimitrios Karnabatidis<sup>1</sup>**

*<sup>1</sup>Interventional Radiology Dpt., University Hospital Of Patras, Greece*

*<sup>2</sup>Department Of Nephrology, University Hospital Of Patras, Greece*

**Purpose:** This was a retrospective longitudinal analysis investigating the safety and effectiveness of consecutive treatments with the Lutonix Drug-Coated Balloons (DCB) in dysfunctional arteriovenous access; both fistulae (AVF) and grafts (AVG).

**Materials and Methods:** From January 2015 to December 2017 (3 years), 339 Lutonix DCB were used in 257 procedures of 165 patients with a dysfunctional AVF or AVG. Of these patients, 33 had  $\geq 2$  procedures, adequate data and were included in the analysis. In these patients, 112 procedures were performed (22 treated twice, 4 patients 3 times, 7 patients 4 times, 2 patients 5 times and 3 patients 6 times) using 133 devices. Mean lesion follow-up was 247 days (min. 20 days - max. 908 days). Mean balloon diameter was 8.13mm (3-12mm) and length 63.16mm (40-150mm). Primary outcome measure safety, defined as freedom from any serious adverse event(s) involving the AV access circuit through 30 days for all procedures and target lesion primary patency (TLPP). Secondary outcome measures included investigation of independent factors that may influence outcomes.

**Results:** Safety was reached in all cases (112/112 procedures, 100%). Median TLPP was 227 days for the first intervention and 280 days for the second consecutive intervention [ $p=0.37$ ; Hazard ratio: 1.271 (CI: 0.75-2.16)].

**Conclusion:** Consecutive use of the Lutonix DCB for the treatment of dysfunctional dialysis access was safe. There was no significant difference in TLPP between the 1<sup>st</sup> and 2<sup>nd</sup> procedure, although a numerical improvement was observed. Results suggest consistency in TLPP regardless of the aging arterio-venous access.

OP6

---

**AORTIC STIFFNESS IN DIABETES MELLITUS MAY BE ATTENUATED  
WITH GLUTAMIN DETECTED BY HSP 70 EXPRESSION**

**Abdullah Ozer**

*Gazi University Medical Faculty, Department of Cardiovascular Surgery, Turkey*

**Background:** Diabetes mellitus results in decreased compliance and causes aortic stiffness. Aortic stiffness is a predictor of vascular mortality. Heat shock proteins (HSPs) are known to protect cells that are under stress. Aortic stiffness in the presence of diabetes mellitus and the protective role of glutamine was tested with HSP 70 levels in an experimental rodent model.

**Methods:** Male Sprague-Dawley rats (n = 30) were divided into three groups as Control (Group 1), DM (Group 2) and glutamine-treated DM (Group 3). DM was induced using streptozocin injection. Group 3 rats received two doses of 1000mg/kg glutamine during the fourth week before sacrifice. Blood and infrarenal aortic tissue samples were obtained for analysis at the end of the fourth week.

**Results:** Aortic HSP 70 levels were increased in diabetic rats. When compared with Group 1, the serum HSP 70 levels were significantly increased in Groups 2 and 3. There was a significant difference in aortic HSP 70 with glutamine injection which is detected by the difference between Group 1 and Group 3. Diabetes mellitus interfered with the elastin content of the aorta. There was a significant correlation between the serum glucose and serum and aortic HSP 70 levels and between serum and aortic HSP 70 levels; as well as between severity of diabetes mellitus and aortic elastin levels.

**Conclusions:** Diabetes mellitus results in aortic stiffness and this may contribute to the increase in mortality and morbidity. The expression of HSP 70 may become a therapeutic target which may be augmented with glutamine injection.

OP7

**DECLOTTING PROCEDURES FOR THE TREATMENT OF THROMBOSED VASCULAR ACCESS CIRCUITS.  
A PARAMETRIC META-ANALYSIS OF 17 STUDIES INCLUDING 3000 ENDOVASCULAR PROCEDURES**

**Michail Theofanis<sup>1</sup>, Panagiotis Kitrou<sup>1</sup>, Konstantinos Katsanos<sup>1</sup>,  
Panagiotis Papadimitos<sup>1</sup>, Maria Karahaliou<sup>1</sup>, Stavros Spiliopoulos<sup>2</sup>,  
Dimitrios Karnabatidis<sup>1</sup>**

*<sup>1</sup>Interventional Radiology Dpt., University Hospital Of Patras, Greece*

*<sup>2</sup>2nd Department Of Radiology, Interventional Radiology Division,  
Attikon University Hospital, Athens, Greece*

**Purpose:** To evaluate the effectiveness of different types of declotting procedures for the treatment of thrombosed arteriovenous grafts (AVGs) and fistulas (AVFs).

**Materials and Methods:** Review of the literature provided 17 studies since 2001. There were 8 retrospective and 9 prospective studies, including 1807 patients, undergoing 3000 procedures in 1067 AVGs and 409 AVFs. Lyse and wait, pulse spray, pharmaco-mechanical, lysis-assisted balloon thrombectomy, mechanical and thrombo-aspiration declotting procedures were included. Primary outcome measure was postintervention assisted primary patency (PAPP). Secondary outcome measures included independent factors that could influence patency.

**Results:** In total at 6, 12 and 24 months PAPP was 54.8% (CI: 44.8-67%), 41.6% (CI: 30.4-57%) and 26% (CI: 17-39.7%) respectively with a median of 11 months. There was a significant difference in PAPP in favor of AVFs compared with AVGs at 24 months [60.2% (CI: 44-82%) vs. 14.8% (CI: 7.4-29.7%),  $p < 0.01$ ]. There was no statistically significant difference between procedures having thrombectomy (TE) or thrombolysis (TL) as a primary declotting method at 2 years [TE: 27.9% (CI: 19-41.3%) vs. TL: 21.6 (CI: 4.7-98.3%),  $p = n.s.$ ] A significant difference was observed when older (<2009) with newer (>2009) studies were compared at 12 months [NEW: 50.1% (CI: 34.3-73%) vs. OLD: 30.4% (CI: 19.4-47.7%),  $p < 0.01$ ]

**Conclusion:** Declotting procedures were significantly more effective in AVFs improving their PAPP results over time. None of the main categorical methods described in literature had significantly better results over the other.

OP8

**A META-ANALYSIS OF RANDOMIZED TRIALS COMPARING BOVINE PERICARDIUM AND OTHER PATCH MATERIALS FOR CAROTID ENDARTERECTOMY**

**Pavlos Texakalidis<sup>1</sup>, Stefanos Giannopoulos<sup>2</sup>, Nektarios Charisis<sup>3</sup>, Spyridon Giannopoulos<sup>4</sup>, Theofilos Karasavvidis<sup>5</sup>, Pascal Jabbour<sup>6</sup>, George Koullias<sup>7</sup>**

<sup>1</sup>*Aristotle University of Thessaloniki, Thessaloniki, Greece*

<sup>2</sup>*251 HAF and VA Hospital, Athens, Greece*

<sup>3</sup>*401 General Military Hospital, Athens, Greece*

<sup>4</sup>*Medical School, Kapodistrian University of Athens, Athens, Greece*

<sup>5</sup>*Medical School, Aristotle University of Thessaloniki, Thessaloniki, Greece*

<sup>6</sup>*Department of Neurosurgery, Thomas Jefferson University, Philadelphia, Pennsylvania, USA*

<sup>7</sup>*Division of Vascular and Endovascular Surgery, Stony Brook University Hospital, Stony Brook, New York, USA*

**Objective:** Patch angioplasty during carotid endarterectomy (CEA) is commonly used to treat symptomatic and asymptomatic carotid artery stenosis. Our objective was to compare the different patch materials that are currently available (synthetic vs. venous vs. bovine pericardium) in terms of short and long-term outcomes.

**Materials & Methods:** This study was performed according to the PRISMA guidelines and eligible randomized control trials (RCTs) were identified through a comprehensive search of PubMed, Scopus and Cochrane Central published until September 2017. A meta-analysis was conducted with the use of a random effects model. The I-square statistic was used to assess for heterogeneity. Outcomes of interest were 30-day stroke, transient ischemic attack (TIA), myocardial infarction (MI), neck wound infection, local hematoma, carotid artery thrombosis, cranial nerve (CN) injury and death. Long-term outcomes investigated were stroke, death and restenosis.

**Results:** Eighteen studies and 3,234 patients were included. The risk of 30-day stroke (RR: 1.00; 95% CI: 0.45 – 2.19; I<sup>2</sup>=0%), TIA (RR: 1.14; 95% CI: 0.41 – 3.19; I<sup>2</sup>=0%), MI (OR: 0.75; 95% CI: 0.14 – 3.97; I<sup>2</sup>=0%), death (RR: 0.53; 95% CI: 0.21 – 1.34; I<sup>2</sup>=0%), wound infection (RR: 1.84; 95% CI: 0.43 – 7.81; I<sup>2</sup>=0%), carotid artery thrombosis (RR: 1.47; 95% CI: 0.44 – 4.97; I<sup>2</sup>=0%), CN palsy (RR: 1.21; 95% CI: 0.53 – 2.77; I<sup>2</sup>=0%) and long-term stroke (RR: 2.33; 95% CI: 0.76 – 7.10; I<sup>2</sup>=0%), death (RR: 1.09; 95% CI: 0.65 – 1.83; I<sup>2</sup>=0%) and restenosis >50% (RR: 0.48; 95% CI: 0.19 – 1.20; I<sup>2</sup>=0%) were similar between the synthetic vs. venous patch. Also, no differences in terms of 30-day stroke (RR: 0.31; 95% CI: 0.02 – 5.16; I<sup>2</sup>=63.1%), TIA (RR: 0.49; 95% CI: 0.14 – 1.76; I<sup>2</sup>=0%), death (RR: 0.74; 95% CI: 0.05 – 10.51; I<sup>2</sup>=31.7%), carotid artery thrombosis (RR: 0.13; 95% CI: 0.02 – 1.07; I<sup>2</sup>=0%) and long-term restenosis >70% (RR: 0.15; 95% CI: 0.01 – 2.29; I<sup>2</sup>=70.9%) were detected between the synthetic polytetrafluoroethylene vs. Dacron patch groups. The comparison between the bovine pericardium vs. synthetic patch did not yield any statistically significant results in terms of 30-day stroke (RR: 1.44; 95% CI: 0.19 – 10.79; I<sup>2</sup>=12.7%), TIA (RR: 1.05; 95% CI: 0.11 – 10.27; I<sup>2</sup>=0%), local neck hematoma (RR: 4.01; 95% CI: 0.46 – 34.85; I<sup>2</sup>=0%) and death (RR: 4.01; 95% CI: 0.46 – 34.85; I<sup>2</sup>=0%).

**Conclusions:** Closure of the carotid arteriotomy with any patch material seems to be similar in terms of short and long-term CEA outcomes. However, additional randomized trials with adequate follow-up periods are needed to compare the bovine pericardium patch to other patch materials.

OP9

**TAILORING OF CH-EVAR TO VARIOUS ANATOMIC CHALLENGES WITH THE CURRENTLY AVAILABLE EN-  
DOGRAFTS IS FEASIBLE AND EFFECTIVE TREATMENT**

**Petroula Nana, Georgios Kouvelos, Konstantinos Spanos, Christos Karathanos,  
Athanasios Giannoukas, Miltiadis Matsagkas**

*Department of Vascular Surgery, Faculty of Medicine, School of Health Sciences,  
University of Thessaly, Larissa, Greece*

**Aim:** To report our single center experience and results with the use of chimney technique (ch-EVAR) for juxtarenal abdominal aortic aneurysm treatment.

**Methods:** All patients treated with ch-EVAR between May 2016 and March 2018 were retrospectively reviewed. They had proximal landing zones precluding any standard endovascular intervention and were at high risk for open surgery. Follow-up surveillance protocol included CTA before discharge, at 1 month, 1 year and yearly thereafter.

**Results:** Twenty-one patients (19 males; 72.4±6.9 years) underwent chimney procedures for 37 renal and 4 superior mesenteric arteries. Ten patients received an Endurant, eight a Nellix, while two an Incraft endovascular device. The median preoperative proximal neck length was 3mm, while the median new neck length, 21.5 mm. All target vessels received a balloon expandable stent graft, while in 12 vessels relining with a self-expandable stent was achieved. Primary technical success was 100%. 30-day mortality was 14.3%. One patient suffered a stroke. During a 12-month median follow-up period, freedom from target vessel occlusion was 87.3%. Two patients had a small gutter endoleak, without sac diameter augmentation. There were two target vessel restenoses, one treated by endovascular means. One type III endoleak was treated with the use of an iliac bridging stent-graft. Freedom from chimney graft-related reinterventions at 3 months was 87.3%.

**Conclusion:** Ch-EVAR for juxtarenal AAA repair allows tailoring to each patient's anatomy and seems a feasible and safe option, at least in the short-term. Despite the minimal invasive nature of the procedure, these patients need a meticulous perioperative care.

OP10

**INITIAL EXPERIENCE WITH THE COVERA COVERED STENT FOR THE TREATMENT OF DYSFUNCTIONAL OR THROMBOSED ARTERIO-VEINUS GRAFTS. A RETROSPECTIVE ANALYSIS OF 43 PATIENTS**

**Panagiotis Papadimitos<sup>1</sup>, Panagiotis Kitrou<sup>1</sup>, Michail Theofanis<sup>1</sup>,  
Nicolaos Christeas<sup>1</sup>, Maria Karahaliou<sup>1</sup>, Spyros Papadoulas<sup>2</sup>,  
Konstantinos Katsanos<sup>1</sup>, Dimitrios Karnabatidis<sup>1</sup>**

<sup>1</sup>*Interventional Radiology Dpt., University Hospital Of Patras, Patras, Greece*

<sup>2</sup>*Vascular Surgery Dpt., University Hospital Of Patras, Patras, Greece*

**Purpose:** To retrospectively evaluate the safety and effectiveness of the Covera covered stent (CS) for the treatment of dysfunctional or thrombosed arterio-venous grafts (AVGs).

**Materials and Methods:** Within 21 months (February 2016 - November 2017), 61 patients underwent CS placement in our department for the treatments of their dysfunctional AVGs. Data were available for 43 patients, undergoing 43 procedures, using 43 devices. Mean follow-up was 214 days (20-524 days). Lesion characteristics were as follows: 33 cases with venous-graft anastomosis (VGA) stenosis, 7 cases of puncture zone stenosis, 12 cases of in-stent-graft (SG) stenosis, 5 cases of pseudoaneurysm treatment. Twenty-six patients presented with thrombosis while 26/43 case were restenotic lesions. Primary outcome measure was target lesion primary patency (TLPP) at six months, while secondary outcome measures included factors influencing primary outcome.

**Results:** Technical success was 100%. TLPP was 60.64% at six months (median TLPP 264 days). During the whole follow-up period 17 AVGs were thrombosed and 11 cases required a redo procedure. There was no significant difference in terms of TLPP when de novo lesions were compared with restenotic, in SG restenosis vs. non in-SG stenosis, patients presented or not with thrombosis, or whether lesion was placed in the puncture zone or in VGA. A significant difference was observed between cases presented with thrombosis after treatment vs. those that were not thrombosed (133 vs. 285 days respectively.  $p=0.007$ ).

**Conclusion:** Use of the Covera CS for AVG treatment is safe and effective in every case presented in this retrospective analysis.

OP11

**12-MONTH OUTCOMES OF COMBINED DIRECTIONAL ATHERECTOMY WITH ANTI-RESTENOTIC THERAPY (DAART) FOR COMMON FEMORAL ARTERY LESIONS**

**Angeliki Argyriou<sup>1</sup>, Konstantinos Stavroulakis<sup>2</sup>, Theodosios Bisdas<sup>1</sup>,  
Giovanni Torsello<sup>2</sup>, Euthymios Beropoulos<sup>1</sup>**

<sup>1</sup>*Department of Vascular and Endovascular Surgery, St. Franziskus Hospital, Muenster*

<sup>2</sup>*Department of Vascular and Endovascular Surgery, University Clinic, Muenster*

**Introduction:** Drug coated balloon (DCB) angioplasty and combined directional atherectomy with anti-restenotic therapy (DAART) are associated with satisfying outcomes in the treatment of superficial femoral- and popliteal-arterial disease. However, data concerning the performance of both modalities for common femoral artery (CFA) lesions are limited.

**Methods:** A retrospective review was conducted on patients treated by either DCB angioplasty alone or DAART for CFA lesions between October 2011 and July 2016. The primary measure outcome of this study was primary patency rate (PPR). Secondary outcomes were technical success rate (TSR), secondary patency rate (SPR) and freedom from clinically driven target lesion revascularization (TLR).

**Results:** Forty-seven patients (n=47) were included into this analysis (DCB: n=26, 55%). Most patients presented in both groups with lifestyle limiting claudication (54% vs 71%, P= .25). Mean lesion length (39±14 mm vs 34±16 mm, P= .31) and vessel calcification (65% vs 52%, P= .37) were comparable between the two groups. Nonetheless chronic total occlusion of the treated vessel was more frequent in the DAART group (0% vs 19%, P=0.02). TSR following DCB angioplasty and DAART was 89% and 95% (P= .41) respectively. Although not statistically significant there was a trend towards superior 12-month PPR in the DAART group (68% vs 88%, hazard ratio (HR): 0.64; 95% confidence interval CI: 0.22 to 2.81, P= .4). The freedom from TLR did not differ significantly between the two modalities (75% vs 89%; P= .98). SPR at 12 months was higher following DAART (81% vs 100%, P= .03). Bailout stenting- (4% vs 5%, P= .87), vessel perforation- (4% vs 0%, P= .36) and distal embolization- (0% vs 5%, P= .26) rates were comparable between the two groups, whereas DCB angioplasty was associated with higher rates of non-flow limiting dissections (31% vs 5%, P=0.02).

**Conclusions:** Despite the trend observed, vessel preparation with directional atherectomy did not significantly improve the PPR compared to DCB angioplasty alone for CFA atherosclerotic disease. Nonetheless, both modalities were associated with promising 12-month outcomes in this primarily surgically treated vascular territory.



OP12

**EARLY EXPERIENCE WITH THE NELLIX ENDOVASCULAR ANEURYSM SEALING DEVICE:  
A PRELIMINARY COMPARATIVE STUDY**

**Petroula Nana<sup>1</sup>, Georgios Kouvelos<sup>1</sup>, Konstantinos Spanos<sup>2</sup>, Athanasios Giannoukas<sup>2</sup>,  
Miltiadis Matsagkas<sup>1</sup>**

<sup>1</sup>*Department of Vascular Surgery, Faculty of Medicine, School of Health Sciences,  
University of Thessaly, Larissa and University of Ioannina, Ioannina, Greece*

<sup>2</sup>*Department of Vascular Surgery, Faculty of Medicine, School of Health Sciences,  
University of Thessaly, Larissa, Greece*

**Aim:** To assess the preliminary results of the Nellix endovascular device and compare them with those obtained in patients treated with a well-established endograft of the same material and infrarenal fixation, as the Gore Excluder.

**Methods:** A retrospective analysis of prospectively collected data from two university centers from September 2014 to December 2017 identified 42 elective patients treated with the Nellix device, in comparison to a matched group of 42 patients treated with the Excluder stent-graft. Endpoints included technical and clinical success, freedom from any secondary intervention, any type of endoleak and aneurysm related death.

**Results:** Primary technical success was achieved in 100% and no 30-day device related complication or death occurred. Radiation burden ( $p=0.04$ ) and contrast media ( $p=0.002$ ) were significantly lower in the Nellix group. Both groups were similar in the procedural duration, post implantation syndrome and in-hospital stay. During a median follow-up period of 14 months, there were no differences in clinical success, freedom from reintervention and aneurysm related death. No type I endoleak was observed. There were 5 type II endoleaks in the Excluder group that spontaneously resolved. No endoleak type II was present in the Nellix group. One patient of the Nellix group suffered from bilateral type Ib endoleak and was treated with bilateral endograft extension to external iliac arteries.

**Conclusion:** The early experience with the Nellix stent graft system is promising, with successful sealing and good short-term results. Further studies are needed to fully evaluate the short and long-term results in comparison to other endografts.

OP13

**REGIONAL SURFACE GROWTH OF ABDOMINAL AORTIC ANEURYSMS DEMONSTRATES THEIR  
NON-UNIFORM EXPANSION**

**Konstantinos Tzirakis<sup>1</sup>, Nikolaos Kontopodis<sup>2</sup>, Emmanouil Tavlas<sup>2</sup>,  
Nikolaos Daskalakis<sup>3</sup>, George Papadopoulos<sup>3</sup>, Christos Chronis<sup>3</sup>,  
Christos Ioannou<sup>3</sup>, Yannis Papaharilaou<sup>1</sup>**

*<sup>1</sup>Institute of Applied and Computational Mathematics (IACM), Foundation for Research  
and Technology-Hellas (FORTH), Heraklion, Crete, Greece*

*<sup>2</sup>Vascular Surgery Unit, Department of Cardiothoracic and Vascular Surgery,  
University Hospital of Heraklion, Crete, Greece*

*<sup>3</sup>Vascular Surgery Unit, Department of Cardiothoracic and Vascular Surgery,  
University of Crete, Medical School*

**Background-aim:** Abdominal aortic aneurysms' (AAAs) growth rate is used as a surrogate marker of rupture risk. Its determination is based on the increase of maximum diameter, although AAA expansion is non-uniform, characterized by significant spatial variability. We aim to quantify AAAs' regional surface growth.

**Methods:** This is a single-institution study including 31 lesions. Each AAA should have one baseline and one follow-up CT scan. From those, 3-Dimensional AAA models were reconstructed using dedicated software. Change in maximum orthogonal diameter and total aneurysm volume were recorded in order to calculate annual growth rate.

Regional surface growth was quantified using the VascForm algorithm which is based on non-rigid point cloud registration and iterative closest point analysis.

Maximum and average surface growth were calculated and correlated with the diameter/volume growth rates. Spearman rho correlation coefficients were calculated and statistical significance was tested.

**Results:** Median average annual surface growth was 6.7%(0%-68%) and maximum surface growth was 26%(12%-444%). Median diameter increase was 3.1mm. There was strong evidence of a moderate correlation between maximum diameter and average as well as maximum surface growth (rho 0.38 p=0.045, rho 0.46 p=0.014 respectively). Regarding volumes, there was strong evidence of a very strong association with average and a moderate association with maximum surface growth rate (rho 0.87 p=0.001, rho 0.54 p=0.009 respectively). In 48% of cases maximum surface growth occurred away from the site of maximum diameter.

**Conclusion:** Surface growth provides a means to evaluate spatial distribution of AAA expansion which may be valuable for rupture risk prediction.

OP14

**COMPARISON OF THE PRIMARY PATENCY BETWEEN OPEN AND ENDOVASCULAR REPAIR OF POPLITEAL ARTERY ANEURYSMS**

**Petroula Nana<sup>2</sup>, Konstantinos Mpatzalexis<sup>1</sup>, Georgios Kouvelos<sup>2</sup>,  
Nikolaos Rousas<sup>1</sup>, Katerina Drakou<sup>1</sup>, Ioannis Vasilopoulos<sup>1</sup>,  
Athanasios Giannoukas<sup>1</sup>, Miltiadis Matsagkas<sup>2</sup>**

<sup>1</sup>*Department of Vascular Surgery, Faculty of Medicine, School of Health Sciences,  
University of Thessaly, Larissa, Greece*

<sup>2</sup>*Department of Vascular Surgery, Faculty of Medicine, School of Health Sciences,  
University of Thessaly, Larissa and University of Ioannina, Ioannina, Greece*

**Aim:** Open repair is the gold standard of treatment for popliteal artery aneurysms. Endovascular repair may be an alternative technique in high risk patients. The aim of this study was to present our experience on PAA treatment, concerning early and long-term graft patency and possible affective factors.

**Methods:** Between 2010 and 2017 in two university centers, 23 patients (median age 74.5±7.5 years; 93% male;) were treated for 28 PAAs. Open repair with a vein or PTFE graft was used in 18 aneurysms while 10 aneurysms were treated with the endovascular technique. During follow-up, all patients underwent a duplex ultrasound at the 1st and 6th month. Demographics, comorbidities, medical treatment and 30-day and 6-month graft patency were analyzed. All patients were contacted to evaluate long-term patency through a clinical assessment.

**Results:** In 6-month follow-up, primary patency was 85.6%, with no statistically important difference between the two techniques. No reintervention or death was recorded. A patient treated with open repair after an aneurysm thrombosis underwent a transmetatarsial amputation during first post-operative month. Graft patency was not associated with statin (log rank=1.57, p=0.21) or dual antiplatelet therapy (log rank=0.289, p=0.59). Long term patency revealed less encouraging results. No reintervention or death was recorded. Beside graft patency and current clinical situation, most patients declare to be satisfied.

**Conclusion:** In our experience, 6-month follow-up graft patency is sufficient for both techniques. This study revealed no predictive factor that may affect patency. Long-term follow up reveal less satisfying results. Further studies and reviews are required.

OP15

**PROFILING POST-EVAR MORPHOMETRY AND HEMODYNAMICS THROUGH IMAGE-BASED COMPUTATIONAL ANALYSIS: COMPARISON AMONG ENDOVASCULAR DEVICES**

**Anastasios Raptis<sup>1</sup>, Paola Tasso<sup>2</sup>, Michalis Xenos<sup>1,3</sup>, Maurizio Lodi Rizzini<sup>2</sup>,  
Diego Gallo<sup>2</sup>, Umberto Morbiducci<sup>2</sup>, Athanasios Giannoukas<sup>1,4</sup>,  
Miltiadis Matsagkas<sup>1,4</sup>**

<sup>1</sup>*Institute of Vascular Diseases, Laboratory for Vascular Simulations, Ioannina, Greece*

<sup>2</sup>*Department of Mechanical and Aerospace Engineering, Politecnico di Torino, Torino, Italy*

<sup>3</sup>*Department of Mathematics, University of Ioannina, Ioannina, Greece,*

<sup>4</sup>*Department of Vascular Surgery, Medical School, University of Thessaly, Larissa, Greece,*

**Background.** Endovascular aneurysm repair (EVAR) results in redirection of blood through the deployed endograft (EG). Adverse post-EVAR events leading to reintervention or even to a fatal scenario are possible. Our objective was to identify possible unique post-implantation morphological and hemodynamic EG characteristics.

**Methods.** Pre- and post-EVAR CT scans of AAA subjects treated either with Endurant or Excluder EGs (N=10 per EG) were reconstructed. Hemodynamic descriptors such as time- and surface-averaged wall shear-stress (TAWSS, AWSS), along with helicity-based indexes, are quantitatively compared with the hemodynamics in healthy vascular models (N=10). A complementary centerline-based geometrical analysis of the post-EVAR infrarenal vascular region was carried out.

**Results.** Regarding hemodynamics, regions with higher TAWSS are larger in Excluder and healthy subjects than in Endurant subjects. Patients treated with Endurant presented the lowest AWSS, while the highest value is found for Excluder patients. Regarding morphometry, treated subjects present a higher number of torsion peak values than healthy subjects, located close to the bifurcation in Excluder group, and in the limbs in Endurant group. As an average, patients treated with Endurant presented the highest values of curvature and torsion in the limbs.

**Conclusion.** The findings indicate that the clinically observed propensity to thrombogenicity in EG devices can be explained in terms of local hemodynamics while reportedly pro-thrombotic hemodynamic structures correlate with the postoperative aortoiliac geometry. In perspective, our study suggests that future clinical follow-up studies could incorporate geometrical analyses, monitoring shape variations that can cause clinically significant hemodynamic disturbances.

OP16

**TREATMENT OF ABDOMINAL AORTIC ANEURYSMS IMMEDIATELY INCREASES  
ARTERIAL STIFFNESS WHICH MAY NEGATIVELY AFFECT CARDIAC FUNCTION**

**George Papadopoulos<sup>1</sup>, Maria Marketou<sup>2</sup>, Nikolaos Kontopodis<sup>1</sup>, Alexandros Patrianakos<sup>2</sup>,  
Emmanouil Tavlas<sup>1</sup>, Christos Chronis<sup>1</sup>, Stavros Stratakis<sup>3</sup>, Frangiskos Parthenakis<sup>2</sup>, Christos Ioannou<sup>1</sup>**

*<sup>1</sup>Vascular Surgery Unit, Department of Cardiothoracic and Vascular Surgery, University of Crete,  
Medical School, Crete, Greece*

*<sup>2</sup>Cardiology Department, University of Crete, Medical School, Crete, Greece*

*<sup>3</sup>Nephrology Department, University of Crete, Medical School, Crete, Greece*

**Background/Aim:** Treatment of abdominal aortic aneurysms (AAAs) by open or endovascular means involves the insertion of a rigid synthetic graft or endoluminal stent-graft inside the arterial system which may alter overall stiffness and peripheral resistance, significantly influencing central hemodynamics with implications in cardiac function. Pulse Wave Velocity (PWV) is the most commonly used surrogate marker of arterial stiffness, which may present significant changes after open or endovascular aortic procedures. We aim to record changes in PWV immediately after elective AAA treatment and potential effects in cardiac function.

**Methods:** Consecutive patients scheduled to undergo AAA repair with either open surgical or endovascular treatment in a single institution had carotid-femoral PWV measurements pre-operatively and 1-week post-operatively in order to determine changes in arterial stiffness. The Complior SP, (Alam Medical, Vincennes, France) device was used. Moreover, standard conventional transthoracic and two-dimensional speckle tracking echocardiography at baseline and 7 days after the intervention was performed

**Results:** Fifty four patients were included. PWV significantly increased post-operatively (from 10.6cm/sec at baseline to 12.5cm/sec after 1week,  $P<0.001$ ). At the same time ejection fraction showed a trend towards reduction which did not reach statistical significance. Left ventricular global longitudinal peak strain significantly deteriorated after the procedure (from  $-19.3 \pm -4.7$  % at baseline to  $-17.2 \pm -5.9$ % at 1 week,  $p = 0.03$ ).

**Conclusions:** A significant increase in arterial stiffness as represented by PWV is observed after AAA treatment which negatively affects indices of cardiac function.

OP17

**12-MONTH RESULTS OF OCT-GUIDED ATHERECTOMY WITH ANTI-RESTENOTIC THERAPY  
IN THE TREATMENT OF FEMOROPOPLITEAL LESIONS**

**Angeliki Argyriou<sup>1</sup>, Euthymios Beropoulos<sup>1</sup>, Arne Schwindt<sup>1</sup>, Theodosios Bisdas<sup>1</sup>,  
Giovanni Torsello<sup>1</sup>, Konstantinos Stavroulakis<sup>2</sup>**

*<sup>1</sup>Department of Vascular and Endovascular Surgery, St. Franziskus Hospital, Muenster*

*<sup>2</sup>Department of Vascular and Endovascular Surgery, University Clinic, Muenster*

**Purpose:** Optical coherence tomography (OCT)-guided directional atherectomy enables a real-time visualization of the arterial wall during plaque debulking and might optimize vessel preparation prior to DCB angioplasty. Nonetheless there is a paucity of data reporting on the outcomes of OCT-guided directional atherectomy with anti-restenotic therapy (DAART). Aim of this study was to evaluate the performance of OCT-guided DAART in the treatment of femoropopliteal atherosclerosis.

**Methods:** Patients treated by OCT-guided DAART for femoropopliteal occlusive disease between January 2015 and December 2016 were included into this retrospective, single-center, single-arm analysis. The primary measure outcome of this study was primary patency rate (PPR). Secondary outcomes were technical success rate (TSR), secondary patency rate (SPR) and freedom from target lesion revascularization (TLR).

**Results:** Thirty-three patients (n=33, mean age 67±8 years) and 37 lesions were included into this analysis. The median follow-up time was 15 months (interquartile ratio (IQR): 4-21). The majority of patients presented with lifestyle limiting claudication (n=25, 75%) and de novo atherosclerotic disease (n=25, 68%). Median lesion length was 70 mm (IQR: 27-104), while 35% (n=13) of the lesions were chronic total occlusions. Vessel wall calcification was present in 22% (n=8) of the treated vessels. The mean luminal gain after atherectomy was 52±17% and the median gain after DAART amounted to 68% (IQR: 58-91). The TSR was 95%. The overall 12 months PPR was 93% whereas the SPR and the freedom from TLR at 12 months were 95% and 100% respectively. A single target vessel perforation (n=1, 3%) and 2 peripheral embolizations (n=2, 5%) were observed. The bailout stenting rate was 3% (n=1) and the final angiography did not reveal any flow limiting dissection. An aneurysmatic degeneration of the target vessel was observed in 2 lesions (5%)

**Conclusions:** In this study, OCT-guided DAART was associated with sufficient luminal gain, low rates of bailout stenting and perioperative adverse events and led to very promising 12-month outcomes.

OP18

---

**TIPS AND TRICKS FOR FACILITATING TEACHING OF DOPPLER WAVEFORMS AND ANKLE-BRACHIAL-INDEX  
IN UNDERGRADUATE LEVEL: A PRACTICAL GUIDE**

**Efstratios Georgakarakos<sup>1</sup>, Evgenia Anastasiadou<sup>2</sup>, Marilena Papoutsi<sup>2</sup>,  
Georgios Koufopoulos<sup>2</sup>, George Georgiadis<sup>1</sup>**

*<sup>1</sup>Department of Vascular Surgery, Medical School,  
Democritus University of Thrace, Alexandroupolis, Greece  
<sup>2</sup>Medical School, Democritus University of Thrace, Greece*

**Background:** Although the measurement of Ankle-brachial-Index (ABI) is considered a fundamental skill in the diagnosis and assessment of peripheral arterial disease as well as predictive tool for cardiovascular events, real-world practice shows that current teaching and practice in undergraduate medical curricula is far from ideal.

**Methods:** We present and discuss twelve tips and tricks to facilitate the accurate measurement of ABI and, most importantly, to ensure the proper interpretation of such estimation. The aforementioned points derive from our experience in the field of undergraduate teaching in the sole Medical School of Greece where the undergraduate curriculum includes "Vascular Surgery" as core subject.

**Results:** Attention to the examiner's hand position is advised against the subtle movements of the patient's foot while inflating the manometer along with discrimination between the venous and the attenuated arterial signal. The significance of ABI interpretation with practical clinical examples is underlined. The use of portable color Duplex in the bedside teaching augments the comprehension of vascular physiology. The arteriovenous shunt represents the ideal example to understand the effect of changes in peripheral resistance. A minimum of 20 ABI measurements is suggested.

**Conclusions:** Teaching of basic principles of vascular examination can be an intriguing task and the acquaintance of practical skills is a demanding process needing commitment, repetitive exercising and combination of theory and practice. The understanding of Doppler arterial waveforms should be implemented in the interpretation of ABI, especially in challenging cases.

OP19

**FACTORS ASSOCIATED WITH ELIMINATION OF ENDOLEAK TYPE II DURING 12-MONTH PERIOD AFTER ENDOVASCULAR ABDOMINAL AORTIC ANEURYSM REPAIR**

**Petroula Nana<sup>1</sup>, Konstantinos Spanos<sup>1</sup>, Georgios Kouvelos<sup>1</sup>, Stylianos Koutsias<sup>1</sup>, Eleni Arnaoutoglou<sup>2</sup>, Athanasios Giannoukas<sup>1</sup>, Miltiadis Matsagkas<sup>1</sup>**

*<sup>1</sup>Department of Vascular Surgery, Faculty of Medicine, School of Health Sciences, University of Thessaly, Larissa, Greece*

*<sup>2</sup>Department of Anesthesiology, Faculty of Medicine, School of Health Sciences, University of Thessaly, Larissa, Greece*

**Aim:** To examine the progress of ET II during the post-operative 12 months period after EVAR and to identify the factors that may be associated with its elimination.

**Methods:** Between 2006 and 2017, 881 patients who underwent EVAR entered a prospective database. Patients with ET II at 1st month CTA were categorized in: group 1; elimination of ET II at 12 months CTA vs. group 2; persistence of ET II at 12 months CTA. Demographics, intra-operative details and 12-month CTA were analyzed. Patients that developed ET II after 1<sup>st</sup> year were excluded.

**Results:** 140 (16%) patients (mean age 71.7±8.5 years; 93.5% male) were eligible for the study. 92% were asymptomatic. Group 1 included 58 patients and group 2, 82. The mean AAA diameter was 60±11 mm, with 44% receiving a supra-renal fixation endograft. 62% of the patients received at least an extra limb extension. An internal iliac occlusion (IIA) intra-operatively was undertaken in 20 patients. At 12 month's CTA, the mean sac regression was higher in group 1 (group 1, -3±4 mm; group 2, 0.55±3 mm, P=0.000). During 12-month follow-up, 4 access related re-interventions and 3 deaths were recorded. Multivariate analysis showed that ET II elimination was associated positively with statin therapy (P=0.047) and sac regression (P=0.000) and negatively with intra-operative IIA occlusion (P=0.03).

**Conclusion:** Statins may instigate ET II elimination during 1<sup>st</sup> post-operative year. Sac diameter is more likely to regress in patients with ET II elimination. IIA occlusion during EVAR may amplify the persistence of ET II.



OP20

**SUPERIOR VENA CAVA SYNDROME STENTING: SINGLE CENTER EXPERIENCE**

**Nikolas Matthaiou<sup>1</sup>, Nikolaos Galanakis<sup>1</sup>, Elias Kehagias<sup>1</sup>, Nikolaos Kontopodis<sup>2</sup>,  
Nelly Kcholcheva<sup>1</sup>, Dimitrios Mavroudis<sup>3</sup>, Dimitrios Tsetis<sup>1</sup>**

<sup>1</sup>*Interventional Radiology Unit, Department of Medical Imaging, University Hospital Heraklion, University of Crete Medical School, Heraklion, Greece*

<sup>2</sup>*Vascular Surgery Unit, Department of Cardiothoracic and Vascular Surgery, University Hospital Heraklion, University of Crete Medical School, Heraklion, Greece*

<sup>3</sup>*Department of Medical Oncology, University Hospital Heraklion, University of Crete Medical School, Heraklion, Greece*

**Background:** Aim: Superior vena cava syndrome (SVCS) is the result of blood flow obstruction through the superior vena cava. It is a medical emergency which requires immediate diagnostic evaluation and treatment. The purpose of this study is to evaluate the technical success and clinical outcome of endovascular stent placement in patients with SVCS and the efficacy of different stent types.

**Methods:** Between February 2005 and October 2017, 153 patients (123 male) with a mean age of 62 (range 33-81) presented with SVCS and treated with placement of self-expanding nitinol stents. The main causes of SVCS were malignancies such as lung cancer (n=116), lymphoma (n=8), thymoma (n=5) while there were also 24 cases of benign SVC thrombosis. The diagnosis of SVCS was based on clinical symptoms/signs and imaging studies such as computed tomography and upper extremity venography. Patients were followed-up for a mean duration of 8.4 months.

**Results:** Technical success was achieved in 150 of 153 patients (98%). There were 2 cases of stent migration to the right atrium and pulmonary artery although without any clinical significance and 1 case of death due to SVC perforation. The follow-up showed total survival of 92.4%, 54%, 22.8% and a primary patency of 93.4%, 79.6% and 70.9% at 1 month, 6 months and 1 year respectively. There were no statistically significant differences in primary patency between the stent groups.

**Conclusions:** Stent placement seems to be a safe and effective treatment option for patients suffering from SVCS offering long-term symptomatic relief.



# **E-Poster Presentations**

**EPP1**

**MULTI-DISCIPLINARY APPROACH TO HIGH LESIONS OF THE CAROTID ARTERY**

**Vasileios Tzilalis<sup>1</sup>, Alexandra Terzoglou<sup>1</sup>, Vasileios Tsiligiris<sup>1</sup>,  
Konstantinos Papoutsis<sup>1</sup>, Ioannis Michailidis<sup>2</sup>, Orestis Tselkas<sup>2</sup>,  
Ioannis Chatzistefanou<sup>2</sup>, Ioannis Kantounakis<sup>3</sup>, Eleftherios Chouliaras<sup>4</sup>,  
Antonios Zoumboulidis<sup>5</sup>**

<sup>1</sup>*Vascular Surgery Department, 401 General Army Hospital Of Athens, Athens, Greece*

<sup>2</sup>*Maxillofacial Surgery Department, 401 General Army Hospital Of Athens, Greece*

<sup>3</sup>*Interventional Radiology Department, 401 General Army Hospital Of Athens, Greece*

<sup>4</sup>*Anesthesiology Department, 401 General Army Hospital Of Athens, Greece*

<sup>5</sup>*Nuclear Medicine Department, 401 General Army Hospital Of Athens, Greece*

**Background/ Aim:** Surgical management of Internal Carotid Artery (ICA) pathologies may often present challenges, both clinical and technical, to the vascular surgeon. The aim of this study is to highlight the importance of inter-disciplinary approach to such cases.

**Methods:** A retrospective review of the surgical records of patients treated in our center for carotid artery pathologies has been performed and complex cases have been identified. Demographic and clinical data, preoperative work-up and surgical approach have been analysed.

**Results:** Of 178 patients presenting with carotid artery stenosis over the last decade (2008-2017), four patients (2.2%) with high carotid lesions required mandibular subluxation, performed by a maxillofacial surgeon, in order to achieve distal Internal Carotid Artery exposure. Eight patients, treated for nine carotid body tumors- neck paragangliomas, were preoperatively scanned by nuclear radiologists with octreotide scintigraphy, to identify synchronous tumors. All eight also underwent biochemical laboratory testing and endocrinological evaluation to examine the functionality of their paragangliomas. Four patients (44%) were 24hours preoperatively embolised, to facilitate the excision of the tumor. Two patients (22%) were subjected to mandibular subluxation and one (11%) to double mandibular osteotomy in order to expose the tumors near the base of the skull. All tumors excised were examined by a pathologist and one was proven to be a vagal paraganglioma.

**Conclusion:** Complex, distal ICA lesions, presenting special challenges to the vascular surgeon, are not very common, but it's important to be managed by highly-skilled, multi-disciplinary teams, to achieve the best treatment.

**EPP2**

**ENDOVASCULAR THORACOABDOMINAL REPLACEMENT IN A PATIENT WITH MARFAN SYNDROME FOLLOWING ABDOMINAL AORTIC DE-BRANCHING**

**Murat Ugurlucan<sup>1</sup>, Yilmaz Onal<sup>2</sup>, Didem Melis Oztas<sup>1</sup>, Feza Ekiz<sup>3</sup>,  
Omer Ali Sayin<sup>1</sup>, Bulent Acunas<sup>4</sup>, Ufuk Alpogut<sup>1</sup>**

*<sup>1</sup>Department of Cardiovascular Surgery, Medical Faculty,  
Istanbul University, Istanbul, Turkey*

*<sup>2</sup>Sultan Abdulhamid Han Hospital, Turkey*

*<sup>3</sup>Department of General Surgery, Istanbul Medical Faculty,  
Istanbul University, Istanbul, Turkey*

*<sup>4</sup>Department of Radiology, Medical Faculty, Istanbul University, Istanbul, Turkey*

**Objective:** Marfan Syndrome is a worldwide distributed, well known autosomal dominant inherited connective tissue disorder. Cardiovascular involvement may lead to life threatening aortic pathologies such as aneurysms and/or dissections. It is known that open surgical therapy of the thoracoabdominal aneurysms has high mortality and morbidity rates.

**Method:** A 27-year-old male patient was referred to our clinic with the diagnosis of giant thoracoabdominal dissecting aneurysm. He had had a history of Benthal-de Bono, aortic arch and infrarenal abdominal aortic replacements and Marfan Syndrome. Hybrid treatment was planned for treatment of the thoracoabdominal dissecting aneurysm.

**Results:** The patient underwent abdominal aortic de-branching, i.e. from right iliac artery to the right renal artery and right iliac artery to left renal, superior mesenteric and celiac artery bypasses. Then, the procedure was followed by endovascular thoracoabdominal stent graft implantation between the aortic arch and infrarenal abdominal aortic grafts. The patient was taken and followed in the intensive care unit for 2 days. The postoperative course was uneventful. The patient discharged from the hospital postoperative 10th day. The 3rd month control computed tomography revealed the thoracoabdominal stent graft and bypasses were patent.

**Conclusions:** Open surgical therapy of the thoracoabdominal aneurysm has serious mortality and morbidity risks such as visceral organ dysfunction and paraplegia. Although with our particular patient we do not propose the method for thoracoabdominal replacement, our hybrid treatment strategy provided a safe alternative to conventional thoracoabdominal aortic replacement even without any blood or blood product use and may be applied in selected patients.

**EPP3**

**CAROTID STENTING VERSUS ENDARTERECTOMY FOR THE TREATMENT OF CAROTID ARTERY STENOSIS:  
CONTEMPORARY RESULTS FROM A SINGLE CENTER STUDY**

**Petroula Nana<sup>1</sup>, Georgios Kouvelos<sup>1</sup>, Vasileios Bouris<sup>1</sup>, Dimitrios Xanthopoulos<sup>1</sup>,  
Michail Peroulis<sup>1</sup>, Eleni Arnaoutoglou<sup>2</sup>, Georgios Papadopoulos<sup>2</sup>,  
Miltiadis Matsagkas<sup>1</sup>**

<sup>1</sup>*Department of Surgery-Vascular Surgery Unit, Faculty of Medicine, School of Health Sciences, University of Ioannina, Ioannina, Greece*

<sup>2</sup>*Department of Anesthesiology, Faculty of Medicine, School of Health Sciences, University of Ioannina, Ioannina, Greece*

**Aim:** To compare the complication rates associated with carotid endarterectomy and carotid stenting for carotid occlusive disease in a University Vascular Center.

**Methods:** All patients admitted to our hospital for carotid revascularization, between March 2001 and March 2015, were analyzed. Eligibility criteria were a symptomatic stenosis  $\geq 70\%$  or an asymptomatic  $\geq 80\%$ . Primary endpoint was a composite of periprocedural death, stroke and myocardial infarction (MI).

**Results:** Totally, 483 patients were admitted. 283 patients (58.6%) underwent CEA and 200 (41.4%) CAS. In total, 301 CEAs and 207 CAS were performed. Symptomatic lesions were similar in both groups ( $p > 0.05$ ). No difference in baseline characteristics was noted. In the CEA group, 30-day stroke rate was 0.9%. Major complications occurred in 3% of the procedures and cranial nerve injury in 4.3%. In the CAS group, technical success was 98.6%. 30-day neurological events included 4 strokes (2%) and 2 TIAs (1%). No peri-procedural death was recorded. Both groups demonstrated similar rates of the composite endpoint, MI, and death during 30-day follow-up. During a follow-up period of  $88 \pm 34$  months in the CEA group, 11 patients experienced a contralateral late stroke (2 fatal). Four carotid arteries developed asymptomatic restenosis. During a follow-up period of  $52 \pm 28$  months in the CAS group, none patient suffered any cerebrovascular event. One asymptomatic restenosis was observed.

**Conclusion:** Short-term outcome is similar in a center providing both techniques. Long-term protection against ipsilateral stroke did not differ between the two methods. More real world comparative data are needed to define the role of each technique.

## EPP4

### THORACIC OUTLET SYNDROME: SINGLE CENTER EXPERIENCE

**Charalampos Stroumpos<sup>1</sup>, Christos Prokakis<sup>1</sup>, Efstratios Koletsis<sup>1</sup>,  
Fotios Eforakopoulos<sup>1</sup>, Nikolaos Charoulis<sup>1</sup>, Emmanouil Margaritis<sup>1</sup>,  
Panagiotis Alexopoulos<sup>1</sup>, Dimitrios Dougenis<sup>2</sup>**

*<sup>1</sup>Cardiothoracic Surgery Department, Faculty of Medicine, School of Health Sciences,  
University of Patras, Patras, Greece*

*<sup>2</sup>Cardiac Surgery Department, Faculty of Medicine, School of Health Sciences,  
National and Kapodistrian University of Athens, Athens, Greece*

**Background-aim:** Thoracic outlet syndrome refers to the compression of the brachial plexus and subclavian vessels at the thoracic outlet. Congenital and acquired anatomic factors are implicated with various neurologic and vascular symptoms. We present our experience in the surgical management and outcome.

**Methods:** Retrospective series of 52 operations performed in 47 patients from 1995 to 2017. There were 11 men and 38 women. Main symptoms were pain and paresthesias in 47 and subclavian vein thrombosis in 5. The operation consisted in scalenectomy associated with resection of the 1<sup>st</sup> rib (38), 1<sup>st</sup> and 2<sup>nd</sup> rib (2), 1<sup>st</sup> rib and cervical rib (4). Five patients had only scalenectomy and 3 underwent resection of 1<sup>st</sup> rib remnant and mobilization of the lesser thoracic muscle from the coracoid. The operation was carried out through the transaxillary approach in 6 and the supraclavicular approach in 46 patients. Three patients were re-operated upon symptom recurrence. Two patients underwent bilateral staged operations.

**Results:** There was no mortality. The morbidity was 15.4% and consisted of bleeding decompressing into the pleural cavity (2), lymphatic leak (2), pneumothorax (1) and symptom relapse within 1 year in 3 patients. Functional outcome was excellent in all but one patient with symptom persistence for more than one year after surgery.

**Conclusions:** Surgical management of thoracic outlet syndrome is associated with acceptable morbidity and excellent functional outcome. The supraclavicular approach allows excellent exposure of the anatomy of the thoracic outlet and enables accurate identification and full release of the offending structures

**EPP5**

**AUTOLOGOUS PLATELET-RICH PLASMA FOR THE TREATMENT OF NON-HEALING ULCERS:  
A COMPARATIVE STUDY**

**Maria Tsachridi<sup>1</sup>, George Galyfos<sup>2</sup>, A. Andreou<sup>3</sup>, Fragiska Sigala<sup>2</sup>,  
Georgios Zografos<sup>2</sup>, Konstantinos Filis<sup>2</sup>**

<sup>1</sup>*Department of Upper GI surgery, Northern General Hospital, Sheffield Teaching Hospitals NHS Trust, Sheffield, UK*

<sup>2</sup>*First Propedeutic Department of Surgery, Hippocraton General Hospital,  
National Kapodistrian University of Athens, Athens, Greece*

<sup>3</sup>*Department of General Surgery, York Hospital, York Teaching Hospital NHS Trust, York, UK*

**Background-Aim:** The use of Platelet-Rich Plasma (PRP) for the treatment of non-healing ulcers is a relatively new technique, although PRP has been associated with satisfying healing and low complication rates. However, data in literature remain sparse. Therefore, aim of this study is to evaluate the potential therapeutic effect of PRP on chronic non-healing ulcers.

**Methods:** This was a prospectively designed study comparing patients treated with PRP (Group A; n=15) with patients treated conventionally without PRP (Control Group B; n=12) for chronic non-healing ulcers as far as major outcomes are concerned. PRP was produced from patient's own peripheral blood sample and was applied on the ulcer once every week.

**Results:** Both groups were similar regarding age, gender, ulcer location, major comorbidities and length of treatment. In Group A, patients experienced a non-significant reduction in area and a significant reduction in depth of the wound, while Group B showed an increase of wound's area after 5 weeks. The healing rate in Group A was stable and positive throughout the recorded treatment period, while Group B showed negative healing rate initially that became positive after the 3<sup>rd</sup> week.

**Conclusions:** Our study shows that appliance of PRP once a week promotes the healing of chronic ulcers. It seems to improve both the depth and healing rate of the ulcer although its effect on the ulcer area seems to be smaller. However, larger comparative series are still needed to confirm these findings.



---

**EPP6**

---

**TWO IS A COMPANY, THREE IS A CROWD**

**Christos Karkos, Christina Papadimitriou, Ioannis Pliatsios, Maria Mitka,  
Konstantinos Alexandris, Ioakeim Giagtzidis, Konstantinos Papazoglou**

*5th Department of Surgery, Aristotle University of Thessaloniki,  
"Hippokratio" Hospital, Thessaloniki, Greece*

An unlikely intraoperative adverse event during endovascular aneurysm repair is contralateral iliac limb maldeployment outside the cannulation gate and within the aneurysm sac. Endovascular salvage may still be possible and requires advancing a guidewire between the misplaced iliac limb and the native iliac artery into the aneurysm and then cannulate, correctly this time, the contralateral gate. A second iliac limb can be deployed and "squeeze" the original one out of the way. A balloon expandable stent may be required to ensure limb patency. Post-operative CT will reveal not two, but three iliac limbs within the sac. We present our experience with two such cases, one with an Anaconda stent-graft and one with the Excluder C3 stent graft. .

**EPP7**

---

**FENESTRATED ENDOVASCULAR REPAIR OF A LARGE PARARENAL ABDOMINAL AORTIC ANEURYSM WITH ANATOMIC VARIETY OF VISCERAL VESSELS USING ANACONDA DEVICE**

**Georgios Vourliotakis<sup>1</sup>, Vasilios Tsiligiris<sup>1</sup>, Theofanis Konstantopoulos<sup>1</sup>,  
Naser Mochament<sup>1</sup>, Georgios Tsiganos<sup>2</sup>, Kyriakos Lazaridis<sup>3</sup>**

*<sup>1</sup>Vascular Surgery Department, 417 NIMTS*

*(Veterans' Fund Army Hospital of Athens), Greece*

*<sup>2</sup>Anesthesiology Department, 417 NIMTS (Veterans' Fund Army Hospital of Athens), Greece*

*<sup>3</sup>Cardiology Clinic, 417 NIMTS (Veterans' Fund Army Hospital of Athens), Greece*

**Background-Aim:** To present our experience in treatment of a complicated case of pararenal abdominal aortic aneurysm (PAAA) with anaconda fenestrated stent-graft.

**Methods:** An 83-year-old man with an 8 cm PAAA was referred to our hospital for endovascular treatment. He had an anatomic variation with common origin of superior mesenteric artery (SMA) and celiac artery (CA), a calcified stenotic angulated left RA origin and aortic dilatation at the level of both renal arteries (RAs). Patient was considered high risk for open operation and was evaluated for endovascular treatment with fenestrated technique. Stent-graft was customized based on the Anaconda system.

**Results:** The patient was treated with a proximal fenestrated body with two fenestrations for the RAs, a double shaped fenestration for the SMA and CA and two limbs for iliac arteries. Four covered stents were used. Kissing balloons were used for flaring of both SMA and CA because of the common origin. Final angiogram revealed visceral vessel perfusion without endoleak. Patient was discharged home on the third postoperative day while his renal function was unchanged. The early follow-up revealed no complications.

**Conclusions:** Fenestrated stent-grafting for PAAA appears safe and effective. However, several technical challenges have to be overcome due to unique vascular anatomy of each patient.

**EPP8**

**LIFE THREATENING RUPTURED IATROGENIC SUPERIOR FEMORAL ARTERY PSEUDOANEURYSM TREATED WITH THROMBIN INFUSION UNDER ULTRASOUND GUIDANCE**

**Ioannis Stamatatos<sup>1</sup>, Eirini Liovarou<sup>2</sup>, Isaak Dimitriadis<sup>3</sup>, Dimitrios Klapsakis<sup>4</sup>, Georgios Anagnostopoulos<sup>3</sup>, Panagiotis Zavalis<sup>2</sup>, Emmanouil Daskalakis<sup>4</sup>, Fragkiskos Tzagkarakis<sup>2</sup>, Dionisios Louverdis<sup>4</sup>, Athanasios Rogdakis<sup>2</sup>**

*<sup>1</sup>Vascular & Endovascular Surgery, General Hospital Nikaia, Piraeus, Greece*

*<sup>2</sup>Radiology & Imaging Sciences Department, General Hospital Nikaia, Piraeus, Greece*

*<sup>3</sup>Second General & Laparoscopic Surgery Department,  
General Hospital Nikaia, Piraeus, Greece*

*<sup>4</sup>Orthopedic Surgery & Trauma Department, General Hospital Nikaia, Piraeus, Greece*

**Background- Aim:** Iatrogenic femoral artery pseudoaneurysms (PSA) typically result from percutaneous access for the purpose of angiography and other interventions. PSAs can be asymptomatic or manifest as a pulsatile mass or thrill. Rarely, they rupture leading to a life-threatening shock. We report the case of a 98 year-old woman who suffered a life-threatening superficial femoral artery pseudoaneurysm rupture after an extracapsular fracture osteosynthesis that was treated with thrombin infusion.

**Methods:** We have received written consent from the patient to present her case for scientific purposes.

**Results:** Although iatrogenic uncomplicated femoral PSA can be treated with ultrasound-guided compression with 70-100% efficacy, thrombin injections guided by ultrasound have become the treatment of choice with the success rates ranging from 93-100%. This is the first case to our knowledge of ruptured iatrogenic femoral pseudoaneurysm treated with thrombin infusion.

**Conclusions:** Rupture of the pseudoaneurysm comprises a vascular emergency. Clinical suspicion and imaging techniques are the cornerstones of timely diagnosis and appropriate management of the condition. The management of iatrogenic pseudoaneurysms demands close and sharp co-operation between radiologist and vascular surgeon. Ultrasound-guided thrombin injection should always be considered after the diagnosis of a ruptured femoral pseudoaneurysm, before emergency surgery is performed.

**EPP9**

**A NOVEL EASILY CONSTRUCTABLE SHUNT FOR CAROTID ENDARTERECTOMY FOR PATIENTS INTOLERANT TO CROSS-CLAMPING**

**Murat Ugurlucan<sup>1</sup>, Didem Melis Oztas<sup>1</sup>, Cagla Canbay<sup>1</sup>,  
Ibrahim Erdinc<sup>2</sup>, Nilgun Bozbuga<sup>1</sup>, Ufuk Alpagut<sup>1</sup>**

*<sup>1</sup>Department of Cardiovascular Surgery, Medical Faculty,  
Istanbul University, Istanbul, Turkey*

*<sup>2</sup>Bozyaka Hospital, Turkey*

**Objective:** Temporary clamping of the carotid arteries for deploying a standard marketed shunt, even less than 30 seconds, may cause severe neurological problems in some patients. In this patient population, we define a novel shunt for safe carotid endarterectomy.

**Methods:** Among 142 patients who underwent carotid endarterectomy between March 2010 and April 2018, 14 (8 men and 6 women; age range 51-79 years) could not tolerate carotid clamping. We used a novel shunt, made from a venous catheter, a three-way stopcock, and a serum line in these patients.

**Results:** Five patients had bilateral lesions and the remainder had unilateral disease. The degree of stenosis ranged from 70 to 95 %. During temporary carotid clamping, loss of consciousness occurred in all patients and tremor in one, in <10 seconds. After releasing the clamps, neurologic function was regained between 15-30 seconds. The novel shunt flow was adequate in all patients and no neurologic deterioration occurred after carotid clamping. The mean carotid clamp time was  $28.11 \pm 14.19$  min. There was no mortality or morbidity. All patients were followed up for a  $14.6 \pm 4.9$  months, uneventfully. The shunt flow was tested ex-vivo using a cardiopulmonary bypass machine filled with blood to simulate human body. Flow of the home-constructed shunt indicated similar rates with Inahara-Pruit and better rates than Javid.

**Conclusions:** A novel shunt, made from an angiocatheter, a three-way stopcock, and a serum line can provide adequate cerebral flow and safe carotid endarterectomy for the patients with carotid artery stenosis, who cannot tolerate even seconds of carotid occlusion.

**EPP10**

**SUCCESSFUL TREATMENT OF TYPE II ENDOLEAKS USING NEUROVASCULAR TECHNIQUES AND PREOPERATIVE CT MAPPING. SHORT SERIES**

**Stavros Kalliafas<sup>1</sup>, Ioannis Bellos<sup>1</sup>, Ioannis Ioannidis<sup>2</sup>, Charalambos Tsatsos<sup>1</sup>**

*<sup>1</sup>Vascular Surgery Clinic, Hygeia Hospital, Athens, Greece*

*<sup>2</sup>Interventional Neuroradiology Department, Hygeia Hospital, Athens, Greece*

**Background.** Endoleaks occur in up to 25% of patients with endovascular abdominal aortic aneurysm repair. Type II endoleaks are the most common ones and they occur from retrograde collateral blood flow from lumbar or inferior mesenteric arteries into the aneurysm sac. We report our experience in treating type II endoleaks using neurovascular techniques (microcatheters, coils and Onyx) and we also notice the importance of preoperative Angio CT mapping.

**Methods.** A microcatheter was advanced from the superior mesenteric artery (via the arc of Riolan or marginal artery of Drummond) to the inferior mesenteric artery or from the internal iliac artery, via the iliolumbar artery, to the lumbar artery. In all successful cases the catheter was advanced all the way to the aneurysm sac. The sac and the feeding vessel were embolized with coils and Onyx. All cases were treated via femoral artery approach. We also examined the importance of identifying a path between the SMA or Lumbar artery and the endoleak cavity during preoperative Angio CT.

**Results:** There were 6 consecutive patients, 5 were treated through the lumbar artery and 1 through the SMA. There was one failure (through lumbar artery approach). This patient was the only one in which we were not able to establish a continuous path between the internal Iliac or SMA and the endoleak site during preoperative Angio CT.

**Conclusions.** Identifying a continuous path to the endoleak site during preoperative Angio CT may predict successful treatment of type II endoleaks using neurovascular techniques.

**EPP11**

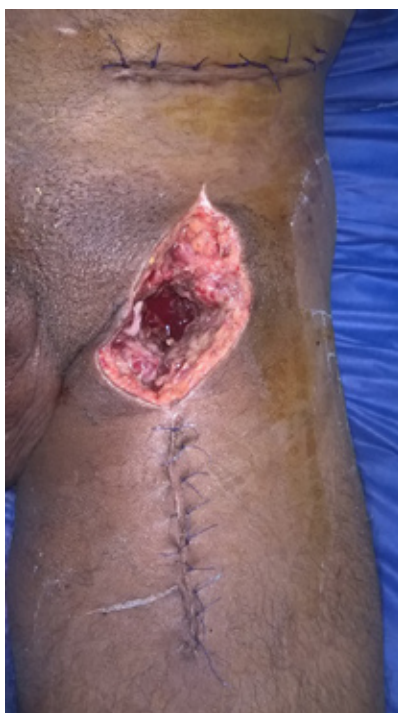**MANAGEMENT OF PSEUDOANEURYSM IN IV DRUG ABUSERS**

**Mostafa Soliman Abdelbary, Amr Nabil Kamel, Abdel Rahman Magdy**

*Vascular surgery department , Faculty of medicine , Ain Shams University*

Infected pseudoaneurysms are a common presentation in intravenous drug abusers with a little consensus as to the optimum management of these patients. Whilst emergency revascularization options are available, excision and ligation of the femoral artery remains the most common operative intervention but risk leaving the patient with critical ischaemia or intermittent claudication. Perioperative predictors of operative outcomes are lacking. In 2016 and 2017 , 20 cases of infected pseudoaneurysms due to intravenous drug abuse are managed by ligation and debridement with follow up of outcomes for a period of 1 year . Predictors of outcome are studied . Only 3 patients required revascularization by extra-anatomical bypass . One of them due to presence of acute ischemia at time of presentation, other 2 cases due to presence of limb threatening critical ischemia. Anticoagulation was given to all patients postoperatively.

Interestingly we found that duration of IV addiction influences the outcome. No mortality or life threatening complications were reported.



**EPP12**

---

**LATE EXPLANTATION OF AN AORTIC ENDOGRAFT AFTER PREVIOUS EVAR  
PROCEDURE: A CASE SERIES**

**George Galyfos, Christiana Anastasiadou, Ioannis Sachmpazidis,  
Georgios Sachsamanis, Sotirios Giannakakis, Anastasios Papapetrou,  
Georgios Kastrisios, Gerasimos Papacharalampous, Chrisostomos Maltezos**

*Department of Vascular Surgery, KAT General Hospital, Athens, Greece*

**Background:** Aortic endograft explantation after previous EVAR has been associated with an increased morbidity and mortality. Our aim is to present a small case series with satisfying results.

**Case series:** Within the past year, 4 patients were treated in our Department with late open conversion and endograft explantation after previous EVAR. Indication for endograft explantation was the following for each case: aortic sac rupture, type I endoleak and graft migration, endograft collapse and thrombosis leading to acute lower limb ischemia, endograft thrombosis leading to critical lower limb ischemia. One endograft was of suprarenal fixation and three endografts were of infrarenal fixation. A thick inflammatory coating of the aortic wall surrounding the endograft was detected intraoperatively in all cases. Three patients underwent open repair with aortobifemoral bypass grafting and one patient underwent an aortobi-iliac bypass grafting. Perioperative mortality was null and no major complication occurred. Midterm follow-up remains uneventful.

**Conclusion:** Aortic endograft explantation after previous EVAR is a challenging surgical procedure that vascular surgeons should be familiar with. When carefully conducted, satisfactory results could be achieved. A close follow-up of patients treated with EVAR is essential for early detection and treatment of such complications.

EPP13

**THE ROLE OF NEW REFLUX OF ACCESSORY VEINS IN CLINICAL RECURRENCE OF VARICOSE VEINS  
AFTER ENDOVASCULAR LASER ABLATION (EVLA)**

**Achilleas Toursidis<sup>1</sup>, Konstantinos Trigonakis<sup>2</sup>**

<sup>1</sup>*Vascular Center, Limassol, Cyprus*

<sup>2</sup>*Department of Vascular and Endovascular Surgery, Euromedica General Clinic of Thessaloniki, Thessaloniki, Greece*

**Introduction:** Recurrent varicose veins are known to be a common problem after surgery. The incidence of those patients with recurrent veins after surgery is reported to be between 20-80% [1-4]. After the appearance of endovascular thermal ablation technique 20 years ago, there is many data accumulated about the recurrence of the varicose veins after thermal ablation. While the main factors for the recurrence after classical ligation and stripping procedure are neovascularization, thigh and calf perforators, considering recurrent veins after the thermal ablation the main cause of recurrence are the side branches of the saphenofemoral junction and specially the anterior accessory vein [5-6]. While during the classic saphenectomy procedure all the side branches of saphenofemoral junction are being ligated, when the thermal ablation is performed the side branches (mainly AAGSV or PAGSV) that end up at the first 2 cm from the saphenofemoral junction or to the epigastric vein are most of the times not being treated when a reflux is absent. These veins could be the cause of a new reflux and recurrence of varicose veins. In order to investigate the treatment strategy for the accessory veins of saphenofemoral junction when they end up to the proximal 2 cm of great saphenous vein or to the epigastric vein non-regarding their size and reflux according to the recurrence of the varicose veins due to a new reflux presentation in them we performed our retrospective study.

**Material and Methods:** Our retrospective study compared two groups of patients. The first group was a large number of patients treated with endovascular laser ablation (EVLA) from 2004 to 2010 to whom the accessory veins that were within the anatomic variation described above were not treated, when not refluxing and were followed up for 5 years. Second group of patients treated from 2011 to 2016 when the accessory veins were treated non-regarding their reflux and followed up until 2018. Patients in both groups were treated with 980 nm laser and bare fiber 600 micron and with 1470 nm laser using radial fibers of 400 and 600 micron as also bare fibers of 400 microns from 2012. The accessory veins were punctured with micropuncture set of 4 Fr when the diameter was from 1 to 3 mm. The patients were followed up in 12, 24, 26, 48, 60 months after the procedure with Duplex Ultrasound.

**Results:** During 12 years 548 legs were treated for the great saphenous vein insufficiency. The first group contained 168 legs, the second group - 380 legs.

In the first group during the follow up after 12 months an increase of the diameter of accessory veins appeared to the 95% of the legs from whom 10% revealed a new reflux without clinical signs. On the 3-rd year of follow up 50 (30%) of the legs revealed a clinical important reflux in the accessory vein and recurrence of the varicose veins due to this reflux. Legs that had to be retreated with EVLA were 10 out of 50 when the length of the insufficient vein was more than 2 cm and with no significant tortuosity, the rest legs were retreated by foam sclerotherapy. In the second group of patients during 4 years of follow up only 4 legs (1%) appeared with new reflux from accessory veins but with no clinical signs of recurrence and didn't need retreatment yet. It is important that in those patients those accessory veins were not initially treated due to a very small size (less than 1 mm). The use of 980 nm and 1470 nm laser as also different types of fibers didn't affect the final results.

**Conclusion:** There is a strong evidence that the accessory veins within the first 2 cm from the saphenofemoral junction or epigastric vein should be treated during the prior procedure even if not refluxing as was done during classic ligation and stripping procedure.



## EPP14

### HOW TO CLAMP AND RE-VASCULARIZE THE BRAIN IF THE PATIENT HAS ONLY SINGLE VESSEL BLOOD SUPPLY TO THE HEAD AND THAT CONTAINS SEVERE STENOSIS?

**Murat Ugurlucan<sup>1</sup>, Yilmaz Onal<sup>2</sup>, Didem Melis Oztas<sup>1</sup>,  
Kubilay Aydin<sup>3</sup>, Ufuk Alpogut<sup>1</sup>**

*<sup>1</sup>Department of Cardiovascular Surgery, Medical Faculty,  
Istanbul University, Istanbul, Turkey*

*<sup>2</sup>Sultan Abdulhamid Han Hospital, Turkey*

*<sup>3</sup>Department of Radiology, Medical Faculty, Istanbul University, Istanbul, Turkey*

**Objective:** Takayasu Arteritis is a granulomatous vasculitis of large vessels. The disease may cause arterial occlusions and aneurysms. Revascularization may be challenging especially in the involvement of the carotid arteries.

**Methods:** A 29-year-old female patient was presented to our clinic orthostatic and post-prandial transient ischemic attacks. She had Takayasu arteritis and severe stenosis of the right common carotid artery and occlusion of left common carotid and both subclavian arteries. Following the consent of the patient, we decided surgical revascularization.

**Results:** Following the carotid arteries dissections, a partial upper median J sternotomy was performed. Two grafts, one 6mm and one 8mm ringed ePTFE grafts were anastomosed end to side to the ascending aorta. The 6mm PTFE graft was anastomosed end to side to the right external carotid artery. The common carotid artery was clamped before the carotid bifurcation and at the origin. The external carotid artery bypass provided pulsatile flow to the brain during the clamp period. The 8mm graft was anastomosed end to side to the right common carotid artery. The 6mm graft was removed from the external carotid artery. The patient was extubated without any neurologic deficit. Her symptoms disappeared immediately. Postoperative course was uneventful and she was discharged home on the 5th post-operative day.

**Conclusion:** During clamping of the common carotid in a patient with single vessel brain supply, an ascending aorta to external carotid artery bypass provides pulsatile continuous blood flow to the internal carotid artery. Cerebral protection has utmost importance during the surgery of the aortic arch and the carotid arteries

---

**EPP15**

---

**MOBILITY, A HEALING FACTOR AFTER DIABETIC FOOT DEBRIDEMENT**

**Tarek Altbrany**

*Cairo curative organization, Cairo, Egypt*

**Introduction:** Diabetic foot infection is a text book chapter with a few text words to read, so limited guide lines to follow, all the available data are just a personal experience. Surgically managed diabetic foot patients especially patients with vascular compromise were instructed not to step on their foot till healing an instruction with so many co-morbidities this case study will prove the opposite after a walking program trial on moderately ischemic feet patients.

**Methods:** 3 diabetic foot patients with vascular compromise were submitted to diabetic foot surgery every one according to the site and the compartment infected, these patients were submitted to a post surgery walking program using total offloading of their body weight on the knee and then wound response observation and documentation was carried on till total healing.

**Results:** After a 3 months follow up period all the 3 patients had reached a fully healthy granulating wound in 50 days with total self dependence in 30 days post operative, good psychological state resuming their daily activities in a satisfying style.

**Conclusion:** Early mobility after diabetic foot debridement is a crucial in the rehabilitation period after surgical debridement of diabetic foot patients that is a sheep way able to avoid so many coasty co-morbidities also able to preserve limb function and patient life style.

## EPP16

### INTERNAL CAROTID ARTERY DISSECTION-SURGICAL TREATMENT

**Didem Melis Oztaş<sup>1</sup>, Metin Onur Beyaz<sup>1</sup>, Yilmaz Onal<sup>2</sup>, Serra Sencer<sup>3</sup>,  
Murat Ugurlucan<sup>1</sup>, Nilgun Bozbuga<sup>1</sup>, Ufuk Alpagut<sup>1</sup>**

<sup>1</sup>Department of Cardiovascular Surgery, Medical Faculty, Istanbul University, Istanbul, Turkey

<sup>2</sup>Sultan Abdulhamid Han Hospital, Turkey

<sup>3</sup>Department of Radiology, Istanbul Medical Faculty, Istanbul University, Turkey

**Objective:** Internal carotid artery dissection is an uncommon pathology and mostly asymptomatic. However symptoms can change from neck pain to severe cerebral ischemic events.

**Methods:** Two patients, a 77 year old male patient and a 61-year old female presented to the clinic with left hemiplegia and neck pain, respectively. Doppler Ultrasonography revealed slow flow with preocclusive stenosis in the right internal carotid artery and dissection with 85 per cent stenosis in the left internal carotid artery in male patient and atherosclerotic plaques in the left internal and common carotid arteries together with left internal carotid artery dissection in the female patient.

**Results:** Operations were performed with regional and infiltration anesthesia. Considering the left hemiplegia, the male patient underwent the right carotid endarterectomy and patchplasty at first. The surgical therapy of the left carotid artery stenosis and localized internal carotid artery dissection was performed after two weeks. The dissected segment with atherosclerotic segment a dacron material in the male patient.

**Conclusions:** The carotid artery stenosis, occlusion and pseudoaneurysm can occur depending on the false lumen in dissection pathology. The early diagnosis and therapy has an utmost importance because of the risk of cerebral ischemia. Endovascular therapy is a minimally invasive method; however, surgical therapy of the atherosclerotic carotid pathologies is still the gold standard. We preferred surgical therapy in stead of endovascular therapy in both patients when we considered atherosclerotic artery pathologies.

**EPP17**

---

**LATE COMMON ILIAC ANEURYSM RUPTURE DUE TO CONTRALATERAL TYPE IB ENDOLEAK  
AFTER PREVIOUS EVAR**

**Anastasios Papapetrou, Georgios Sachsamanis, Ioannis Sachmpazidis,  
George Galyfos, Christiana Anastasiadou, Sotirios Giannakakis,  
Gerasimos Papacharalampous, Chrisostomos Maltezos**

*Department of Vascular Surgery, General Hospital 'KAT', Athens, Greece*

**Background:** Type I endoleaks have been associated with aortic sac enlargement and rupture after previous EVAR procedure. We aim to present an unusual case of late common iliac aneurysm rupture due to contralateral type IB endoleak that was treated endovascularly.

**Case report:** A 75-year-old male patient presented with acute pain and a large pulsatile mass in his right lower iliac fossa. The patient had undergone an EVAR with left iliac branching for abdominal aortic and bilateral common iliac artery aneurysms 6 years ago although he had missed follow-up imaging for the past three years. He underwent an ultrasound examination that showed a possible right-sided endoleak feeding a right iliac artery aneurysm. However, computed tomography (CT) imaging revealed a left-sided type IB endoleak due to extension of the aortic disease leading to contralateral common iliac aneurysm enlargement and rupture. The patient underwent an endovascular repair with the deployment of an iliac extension into the left external iliac artery (16mm in diameter). The postoperative course of the patient was uneventful and a CT imaging 5 days after the procedure showed an adequate sealing of the left common iliac artery and no signs of an endoleak. The course of the patient 4 months after discharge remains uneventful.

**Conclusions:** Type IB endoleak could present even late after the initial EVAR procedure causing contralateral common iliac aneurysm rupture. Therefore, close observation and follow-up is imperative for these patients. Endovascular repair remains the first-line treating strategy in these cases.

**EPP18**

**CEREBRAL PROTECTION DURING AORTIC DE-BRANCHING WITH A TEMPORARY CROSS OVER BYPASS BETWEEN THE EXTERNAL CAROTID ARTERIES - EARLY RESULTS**

**Didem Melis Oztas<sup>1</sup>, Murat Ugurlucan<sup>1</sup>, Metin Onur Beyaz<sup>1</sup>, Yilmaz Onal<sup>2</sup>,  
Omer Ali Sayin<sup>1</sup>, Nilgun Bozbuga<sup>1</sup>, Ufuk Alpagut<sup>1</sup>, Enver Dayioglu<sup>1</sup>**

*<sup>1</sup>Department of Cardiovascular Surgery, Istanbul Medical Faculty,  
Istanbul University, Istanbul, Turkey*

*<sup>2</sup>Department of Radiology, Istanbul Medical Faculty, Istanbul University, Istanbul, Turkey*

**Objectives:** Endovascular therapies of the thoracic aorta may require debranching of the aortic arch. Cerebral protection has significant importance during the procedure.

**Methods:** The technique was performed in the six patients with aortic arch and descending aortic aneurysms. The left main carotid artery and left subclavian artery were separated from the aortic arch and reimplanted to make the endovascular stent grafting possible. The operations were performed under regional anesthesia. In the patients that did not tolerate carotid clamping, the cross bypass between external carotid arteries was made with 6 mm PTFE graft over the skin. An appropriate length 8 mm PTFE graft Y graft was prepared. The proximal anastomosis of the Y graft was made end to side to the right common carotid artery. The left common carotid artery was ligated and one of the branches of the Y graft was anastomosed end to end to the left common carotid artery. Then the cross bypass between external carotid arteries was removed. The left subclavian artery was ligated and the other branch of the Y graft was anastomosed end to end to the subclavian artery. All patients were neurologically stable.

**Results:** Except one patient, all TEVAR procedures were performed in same session. One patient died because of pneumonia 6 months after the operation, two patient died in two years of the operation due to various reasons. Others are being followed uneventfully.

**Conclusions:** A cross over bypass between external carotid arteries provides continuous pulsatile blood flow to internal carotid arteries even in the presence of proximal aortic clamp and a safe procedure.

**EPP19**

---

**TYPE I ENDOLEAK: A RARE COMPLICATION AFTER OPEN ABDOMINAL AORTIC ANEURYSM REPAIR**

**Konstantinos Filis, George Galyfos, Jiannis Tsagos, Gerasimos Bazigos,  
Constantinos Zarmakoupis, Georgios Karantzikos,  
Fragiska Sigala, Georgios Zografos**

*First Propedeutic Department of Surgery, Hippocraton General Hospital, National Kapodistrian  
University of Athens, Athens, Greece*

**Background-Aim:** Endoleaks are frequent complications after endovascular repair of abdominal aortic aneurysms (EVAR). However, endoleaks have been identified in the literature as a rare complication after open repair as well. Therefore, we aim to present such an unusual case.

**Case report:** A 75-year-old male patient underwent a computed tomography (CT) control during his scheduled follow-up 6 months after an elective open repair of an infrarenal abdominal aortic aneurysm (AAA). The primary procedure was uneventful and the patient remained asymptomatic. However, CT imaging revealed an 'endoleak type I'-like formation adjacent to the endograft and an enlargement of the aortic sac. The patient underwent an open procedure that identified a detachment of the proximal anastomosis laterally. The proximal anastomosis was reconstructed. The postoperative course was uneventful. CT imaging after one month showed no endoleak and no increase in AAA sac.

**Conclusions:** Type I endoleaks present rarely after open AAA repair although an invasive treatment is always needed. Open repair of the affected anastomosis remains an effective solution, although endovascular management has proved its efficacy as well.

## EPP20

---

### ATHEROSCLEROSIS RISK FACTORS AND DEGREES OF STENOSIS IN THREE ARTERIAL SITES

**Aikaterini Angeli, Nikolaos Doulamis**

*National Technical University of Athens, Athens, Greece*

**Background:** Atherosclerosis is a multifactorial disease of the arterial tree. The traditional risk factors and other agents, including bacteria, induce the various phenotypes of the disease.

**Methods:** Three hundred and seventy-five vascular cases from an outpatient private setting were studied. Inclusion criteria were the presence of at least one traditional atherosclerosis risk factor, the availability of full medical history and at least two site (carotid, peripheral and/or iliac) vascular ultrasound for each case. Total risk factors, independent risk factors (smoking, number of pack years, hypertension, diabetes, hyperlipidemia, obesity, renal failure, age, gender), heart disease, major vascular events, number of prescribed all-cause and risk factor modification drugs have been investigated in relation to three degrees (<30%, 30-70%, >70%) of arterial stenosis. The various degrees of stenosis among the three sites have also been investigated.

**Results:** Patients with minimal compared to moderate degree of carotid and peripheral stenosis, differed significantly for the majority of traditional risk factors (Mann Whitney test,  $p < 0.001$ ). No significant difference was noticed between medium and severe stenosis for all sites. Among all risk factors, diabetes had the weaker significance for all sites. Iliac atheromatosis presented the less statistical significance for the majority of risk factors and for all degrees of stenosis. Among the three sites the best stenosis match was noticed between carotid and iliac site. The ratio of risk factor to all-cause drugs has a trend towards stability in all site medium and severe stenosis.

**EPP21**

---

**VIABAHN FOR THE TREATMENT OF INTERNAL CAROTID ARTERY PSEUDOANEURYSM - CASE REPORT**

**Christiana Anastasiadou, George Galyfos, George Kastrisios,  
George Sahsamani, Gerasimos Papacharalampous, Chrysostomos Maltezos**

*Vascular surgery department - General hospital of Athens "KAT", Athens, Greece*

**Introduction:** Carotid artery pseudoaneurysm is a rare clinical entity, most commonly as result of neck trauma or iatrogenic intervention. We present a case of false aneurysm of internal carotid artery which was treated with endovascular means.

**Case report:** A 63-year-old male presented at our department complaining of hoarseness, cough and a gradually increasing mass on his neck. Patient's medical history included ipsilateral carotid artery stenosis for which he underwent CEA using synthetic patch (10 years ago) and non-Hodgkin lymphoma for which he underwent tonsillectomy and cervical radiation therapy (9 years ago). Ct angiography of cervical arteries revealed pseudoaneurysm of internal carotid artery (max diameter 1,5cm, length 3,1cm), dissected external carotid artery and normal findings on brain CT. Therapy was provided with the deployment of a self-expandable stent graft across the lesion. Follow-up consisted of clinical examination and duplex ultrasonography, remains without complications six months postoperatively.

**Conclusion:** Open intervention in a previously operated and irradiated neck is technically demanding and carries a significant risk for major complications. Endovascular therapy is safe and should be the first-line therapy in those cases.



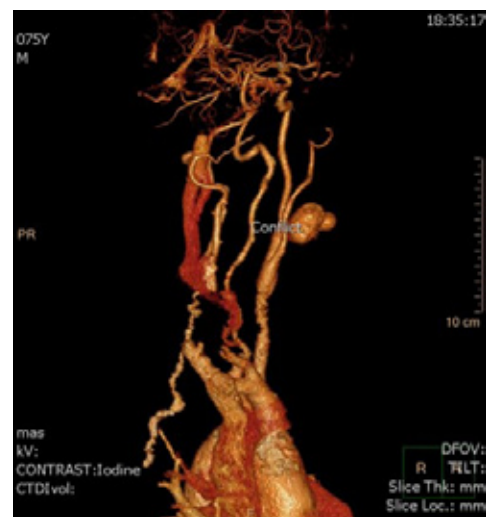
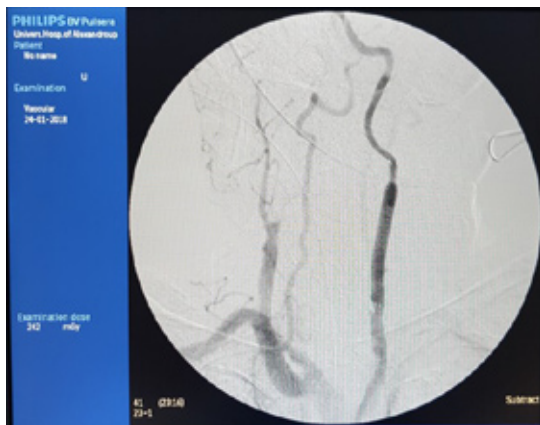
EPP22

**REPEATED CAROTID ARTERY RUPTURE WITH PSEUDOANEURYSM FORMATION DUE  
POST-ENDARTERECTOMY PATCH INFECTION-COMBINED SURGICAL AND ENDOVASCULAR  
MANAGEMENT. A CASE REPORT**

**Christos Argyriou, Kalliopi-Maria Tasopoulou, Stefanos Popidis,  
Efstratios Georgakarakos, Andreas Koutsoumpelis, George S Georgiadis**

*Vascular Department, University General Hospital of Alexandroupolis, Greece*

Post-carotid endarterectomy patch infection with resultant pseudoaneurysm formation is the most feared complication after carotid operation. Although rare, carotid patch infections are associated with high rates of morbidity and mortality, especially when complicated by acute haemorrhage. The definitive treatment involves patch resection and arterial reconstruction, but patient factors will determine whether a redo surgery is appropriate. This is the only case in the literature describing a carotid patch infection complicated by recurrent bleeding episodes and pseudoaneurysms formation which were managed twice by open surgical reconstruction while the last definitive treatment was done endovascularly.



**EPP23**

**ANTERIOR TIBIAL ARTERY PSEUDOANEURYSM: TWO DIFFERENT PATIENTS AND TWO DIFFERENT TREATMENT MODALITIES**

**Didem Melis Oztas, Murat Ugurlucan, Zuhar Torlak, Ufuk Alpogut,**  
**Nilgun Bozbuga, Enver Dayioglu**

*Department of Cardiovascular Surgery, Medical Faculty, Istanbul University, Istanbul, Turkey*

**Objective:** Pseudoaneurysm of the anterior tibial artery is a rare vascular disorder. The most common etiology is penetrating trauma. In this report, we present two patients and two different treatment modalities.

**Methods:** A 22-year-old male patient presented with anterior tibial artery (ATA) pseudoaneurysm after an exterior vehicle traffic accident. Doppler ultrasonography revealed a 3x4 cm pseudoaneurysm of the anterior tibial artery. Compression therapy was tried with angiography but failed; so surgical therapy was planned. A 23-years old male patient was operated for tibial implant placement by orthopedic because of the tibial fracture after exterior vehicle traffic accident. After 3 months, the pulsatile mass was recognized on the front of the right thigh. Doppler ultrasonography revealed a 3,5x2 cm pseudoaneurysm of the anterior tibial artery, and compression therapy by angiography was planned.

**Results:** In the first patient, ATA was patent, so reconstructive surgery was considered. Because of the large arterial defect, ATA was repaired with autolog venous patch. Postoperative course was uneventful and second day the patient was transferred to orthopedic clinic. Second patient underwent angiography for compression therapy. 3 mm balloon was used and after one minute, pseudoaneurysm was thrombosed. Postoperative first day the patient was discharged from the hospital uneventfully.

**Conclusion:** Pathology is usually treated with resection of the pseudoaneurysm and ligation of the anterior tibial artery. But when a patent ATA was detected, arterial reconstruction should be considered. Surgery is definitive treatment modality but in minor arterial defects and pseudoaneurysms compression therapy should be considered as a safe and easy treatment modality

**EPP24**

---

**OPEN ENDARTERECTOMY AND PATCHPLASTY IN PERIPHERAL  
ARTERIAL DISEASES**

**Murat Ugurlucan<sup>1</sup>, Didem Melis Oztas<sup>1</sup>, Cagla Canbay<sup>1</sup>, Ibrahim Erdinc<sup>2</sup>, Ufuk Alpogut<sup>1</sup>**

<sup>1</sup>*Department of Cardiovascular Surgery, Medical Faculty, Istanbul University, Istanbul, Turkey*

<sup>2</sup>*Bozyaka Hospital, Turkey*

**Objective:** Open endarterectomy and patchplasty is an alternative and limb saving therapy for patients with peripheral arterial disease. In this paper, we present the patients underwent open endarterectomy and patchplasty and short term results.

**Materials and Methods:** Between March and November 2018, eleven patients (9 male and 2 female) underwent to endarterectomy and patchplasty. The mean age was 54.5. The computed tomography angiography was used for checking the patency of the procedure.

**Results:** In 9 of the patients, autologous saphenous vein grafts were used for patchplasty. The remaining patients underwent the procedure with the PTFE graft because of the absent suitable saphenous vein and due to abdominal aorta and iliac arteries involvement with disease in one patient. In this patient abdominal aorta and iliac arteries endarterectomy was involved to the procedure. One patient died postoperative 11th day because of the co-morbidities. 3 of them stayed in intensive care unit for two days. 7 of them was taken to the ward uneventfully. Postoperative 1st month control, computed tomography revealed that the arteries were patent.

**Discussion:** In our daily practice, even endovascular and hybrid procedures are increasingly performed, bypass operations continue to be the most common treatment approaches. But absence of the appropriate saphen vein and infection risk of the non-autogenous grafts arises the need for an alternative approach. We believe that endarterectomy methods give a response to this requirement and provides an useful alternative therapy with low cost analysis and without excessive equipment necessity, especially in limb salvage

**EPP25**

---

**COMBINATION OF SINGLE ANTIPLATELET THERAPY AND APIXABAN IN PATIENTS UNDERGOING ENDOVASCULAR PROCEDURES FOR PERIPHERAL ARTERIAL DISEASE**

**Christina Papadimitriou, Maria Mitka, Ioannis Pliatsios, Konstantinos Alexandris, Ioakeim Giagtzidis, Christos Karkos, Konstantinos Papazoglou**

*5th Department of Surgery, Medical School, Aristotle University of Thessaloniki, Hippocratio Hospital, Thessaloniki, Greece*

**Aim:** The aim of this prospective study is to evaluate the safety and efficacy of apixaban, a novel oral anticoagulant, in patients undergoing PTA and/or stenting for peripheral arterial disease (PAD).

**Methods:** From March 2017 to March 2018, 36 patients (28 male) with a mean age of 68 years (range 48-89) were treated for PAD by endovascular means. First dose of apixaban was administered 6-8 hours post-operatively and the treatment was continued for 6 months. Patient follow up was carried out at 6 and 12 months post-operatively by clinical examination and triplex of the lower limb arteries. Study end points were: 30-day mortality, primary and secondary patency, major and minor bleeding events, recurrence of claudication, compliance to treatment and survival at follow up.

**Results:** Six month data were available from 20 patients. The compliance was 90%. One patient reported epistaxis (5%). Re-intervention was necessary in two patients (10%). Six patients (30%) presented with recurrence of claudication, while one patient who presented with critical limb ischemia eventually required amputation (5%). A total of 80% showed clinical improvement.

**Conclusions:** Both efficacy and safety of apixaban were assessed. The use of apixaban in PAD patients undergoing endovascular intervention needs to be further evaluated.

**EPP26**

**TREATMENT OF DACRON GRAFT ANEURYSM OF AORTOBIFEMORAL  
BYPASS GRAFT**

**Murat Ugurlucan<sup>1</sup>, Yilmaz Onal<sup>2</sup>, Mehmet Barbuoglu<sup>3</sup>, Mehmet Akif Onalan<sup>1</sup>, Siraslan Bakhshaliyev<sup>1</sup>,  
Bulent Acunas<sup>3</sup>, Ufuk Alpagut<sup>1</sup>**

<sup>1</sup>*Department of Cardiovascular Surgery, Medical Faculty, Istanbul University, Istanbul, Turkey*

<sup>2</sup>*Sultan Abdulhamid Han Hospital, Turkey*

<sup>3</sup>*Department of Radiology, Medical Faculty, Istanbul University, Istanbul, Turkey*

**Objective:** Dacron grafts are commonly used during surgical revascularization procedures. Graft thrombosis or infection are well known complications. However, aneurysm formation is extremely rare. In this report, we present Dacron graft aneurysm complication of left limb of aortobifemoral bypass graft in a 50-year-old male patient.

**Methods:** The patient underwent aortobifemoral bypass operation in 2010. An 18x9mm, 45cm knitted polyester vascular graft (FlowNit Bioseal, JOTEC Vascular Prosthesis) was used for the procedure. In 2013, he presented with occlusion of right limb of the graft. He underwent cross-over bypass using the saphenous vein between the femoral arteries. He presented to the clinic enlargement of the left femoral pulsatile mass. A computerized tomography angiography indicated Dacron graft dilation (35x31 mm body size and 28x24 mm left leg size) and a 5cm in diameter left femoral aneurysm.

**Results:** The hybrid therapy was planned. He underwent aortouniliac endovascular stent grafting (Medtronic Endovascular, Santa Roja, Calif., US) and surgical removal of the left femoral aneurysm and replacement with an 8mm PTFE graft.

**Conclusions:** Dacron graft aneurysms are rare disorders. Mostly it presents with generalized dilation. The etiology of the pathology is multifactorial; such as fabrication flaws, methods of sterilization, bio-deterioration related to hematomas or infection, and material fatigue. Aneurysm rupture is a very rare complication. Endovascular treatment is a relatively safe and easy option for the treatment of the dilated Dacron grafts.

**EPP27**

**SPLANCHNIC REVASCULARIZATIONS**

**Didem Melis Oztas<sup>1</sup>, Metin Onur Beyaz<sup>1</sup>, Nihat Aksakal<sup>2</sup>, Omer Ali Sayin<sup>1</sup>,  
Murat Ugurlucan<sup>1</sup>, Nilgun Bozbuga<sup>1</sup>, Ufuk Alpogut<sup>1</sup>**

<sup>1</sup>*Department of Cardiovascular Surgery, Medical Faculty, Istanbul University, Istanbul, Turkey*

<sup>2</sup>*Department of General Surgery, Medical Faculty, Istanbul University, Istanbul, Turkey*

**Objective:** The superior mesenteric artery occlusions are rare pathologies; and has high morbidity and mortality rates. We present combined therapy of the chronic superior mesenteric artery occlusion together with aortobiliac occlusive disease.

**Methods:** The fifty-seven years old male patient presented to our clinic with the abdominal pain after meal, claudication in fifty meters, and 20kg weight loss in 3 months. There was aortobiliac occlusive disease in computed tomography angiography. Also there was an occlusion in superior mesenteric artery ostium. Aortobifemoral bypass operation was planned combined with superior mesenteric artery bypass.

**Results:** Through median laparotomy aortobifemoral bypass operation was performed. The saphenous vein was used as a graft and anastomosed to superior mesenteric artery and the body of the aortobifemoral bypass graft. Postoperative course was uneventful and the patient was discharged in the seventh day. In the 6th month control computed tomography angiography, the aortobifemoral bypass graft and the superior mesenteric artery bypasses were patent.

**Conclusions:** Acute or chronic superior mesenteric artery occlusions may cause severe pathologies. Medical therapies, endovascular treatments like ballooning and stenting and surgical therapies are used in treatment. We preferred surgical therapy of the superior mesenteric artery occlusion simultaneously with surgical therapy of the aortoiliac occlusive disease.

**EPP28**

---

**THE USE OF THE HELI-FX™ ENDOANCHOR™ SYSTEM FOR THE TREATMENT OF TYPE 1A ENDOLEAK  
AFTER PREVIOUS EVAR**

**Ioannis Pliatsios, Maria Mitka, Konstantinos Alexandris, Christina Papadimitriou, Ioakeim Giagtzidis,  
Christos Karkos, Konstantinos Papazoglou**

*5th Department of Surgery, Aristotle University of Thessaloniki,  
Hippokratio Hospital, Thessaloniki, Greece*

The Heli-FX™ EndoAnchor™ System is intended to provide fixation and sealing between aortic stent-grafts and the native artery in patients who had exhibited migration or endoleak, or are at risk of such complications. The EndoAnchor may be implanted at the time of the initial stent-graft placement, or during a secondary procedure. The aim of this presentation is to present our technical experience with the use of the device for the treatment of type 1a endoleak.





# Index of Authors

## Invited of Authors

<b>A</b>	
Abdelbary Mostafa Soliman .....	38
Acunas Bulent .....	29, 53
Aksakal Nihat .....	54
Alexandris Konstantinos .....	33, 52, 55
Alexopoulos Panagiotis .....	7, 31
Alpagut Ufuk .....	29, 36, 41, 43, 45, 50, 51, 53, 54
Altbrany Tarek .....	42
Anagnostopoulos Fotis .....	8
Anagnostopoulos Georgios .....	35
Anastasiadou Christiana .....	39, 44, 48
Anastasiadou Evgenia .....	23
Andreou A. ....	32
Angeli Aikaterini .....	47
Argyriou Angeliki .....	16, 22
Argyriou Christos .....	49
Arnautoglou Eleni .....	24, 30
Aydin Kubilay .....	41
<b>B</b>	
Bakhshaliyev Siraslan .....	53
Barbuoglu Mehmet .....	53
Bazigos Gerasimos .....	46
Bellos Ioannis .....	37
Beropoulis Euthymios .....	16, 22
Beyaz Metin Onur .....	43, 45, 54
Bisdas Theodosios .....	16, 22
Bouris Vasileios .....	30
Bozbuga Nilgun .....	36, 43, 45, 50, 54
<b>C</b>	
Canbay Cagla .....	36, 51
Charisis Nektarios .....	13
Charoulis Nikolaos .....	7, 31
Chatzistefanou Ioannis .....	28
Chouliaras Eleftherios .....	28
Christeas Nicolaos .....	15
Chronis Christos .....	18, 21
<b>D</b>	
Daskalakis Emmanouil .....	35
Daskalakis Nikolaos .....	18
Dayioglu Enver .....	45, 50
Dimitriadis Isaak .....	35
Dougenis Dimitrios .....	7, 31
Doulamis Nikolaos .....	47
Drakou Katerina .....	19
<b>E</b>	
Eforakopoulos Fotios .....	7, 31
Ekiz Feza .....	29
Erdinc Ibrahim .....	36, 51
<b>F</b>	
Filis Konstantinos .....	32, 46
Fligou Fotini .....	7
<b>G</b>	
Galanakis Nikolaos .....	9, 25
Gallo Diego .....	20
Galyfos George .....	32, 39, 44, 46, 48
Georgakarakos Efstratios .....	23, 49
Georgiadis S. George .....	23, 49
Giagtzidis Ioakeim .....	33, 52, 55
Giannakakis Sotirios .....	39, 44
Giannopoulos Spyridon .....	13
Giannopoulos Stefanos .....	13
Giannoukas Athanasios .....	6, 14, 17, 19, 20, 24
<b>I</b>	
Ioannidis Ioannis .....	37
Ioannou V. Christos .....	9, 18, 21
<b>J</b>	
Jabbour Pascal .....	13

## Invited of Authors

K		M	
Kalliafas Stavros .....	37	Magdy Abdel Rahman .....	38
Kallidonis P. ....	8	Maltezos Chrysostomos .....	39, 44, 48
Kalogeropoulou Christine .....	7	Margaritis Emmanouil .....	7, 31
Kamel Amr Nabil .....	38	Maris G. Thomas .....	9
Kantounakis Ioannis .....	28	Marketou Maria .....	21
Karahaliou Maria .....	10, 12, 15	Matsagkas Miltiadis .....	6, 14, 17, 19, 20, 24, 30
Karantanas Apostolos .....	9	Matthaiou Nikolas .....	9, 25
Karantzikos Georgios .....	46	Mavroudis Dimitrios .....	25
Karasavvidis Theofilos .....	13	Michailidis Ioannis .....	28
Karathanos Christos .....	14	Mitka Maria .....	33, 52, 55
Karkos Christos .....	33, 52, 55	Mochament Naser .....	34
Karnabatidis Dimitrios .....	8, 10, 12, 15	Morbiducci Umberto .....	20
Karpetas George .....	8	Moulas Anargyros .....	8
Kastrisios Georgios .....	39, 48	Mpatzalexis Konstantinos .....	19
Katsanos N. Konstantinos .....	8, 10, 12, 15	N	
Kcholcheva Nelly .....	25	Nana Petroula .....	6, 14, 17, 19, 24, 30
Kehagias Elias .....	9, 25	O	
Kitrou M. Panagiotis .....	8, 10, 12, 15	Onalan Mehmet Akif .....	53
Klapsakis Dimitrios .....	35	Onal Yilmaz .....	29, 41, 43, 45, 53
Koletsis Efstratios .....	7, 31	Ozer Abdullah .....	11
Konstantopoulos Theofanis .....	34	Oztas Didem Melis .....	29, 36, 41, 43, 45, 50, 51, 54
Kontopodis Nikolaos .....	9, 18, 21, 25	P	
Kosidekakis Nikolaos .....	9	Papacharalampous Gerasimos .....	39, 44, 48
Koufopoulos Georgios .....	23	Papachristou Evangelos .....	10
Koullias George .....	13	Papadimatos N. Panagiotis .....	8, 10, 12, 15
Koutsias Stylianos .....	6, 24	Papadimitriou Christina .....	33, 52, 55
Koutsoumpelis Andreas .....	49	Papadopoulos George .....	18, 21
Kouvelos Georgios .....	6, 14, 17, 19, 24, 30	Papadopoulos Georgios .....	30
L		Papadopoulos Panagiotis .....	7
Lampropoulos George .....	8	Papadoulas Spyros .....	15
Lazaridis Kyriakos .....	34	Papaharilaou Yannis .....	18
Liovarou Eirini .....	35	Papapetrou Anastasios .....	39, 44
Louverdis Dionisios .....	35	Papazoglou Konstantinos .....	33, 52, 55

## Invited of Authors

Papoutsis Marilena .....	23	Theofanis Michail .....	8, 10, 12, 15
Papoutsis Konstantinos .....	28	Torlak Zuhail .....	50
Parthenakis Frangiskos .....	21	Torsello Giovanni .....	16, 22
Patrianakos Alexandros .....	21	Toursidis Achilleas .....	40
Perisinakis Konstantinos .....	9	Trigonakis Konstantinos .....	40
Peroulis Michail .....	30	Tsachridi Maria .....	32
Pliatsios Ioannis .....	33, 52, 55	Tsagos Jiannis .....	46
Popidis Stefanos .....	49	Tsatsos Charalambos .....	37
Prokakis Christos .....	7, 31	Tselkas Orestis .....	28
<b>R</b>		Tsetis Dimitrios .....	9, 25
Raptis Anastasios .....	20	Tsiganos Georgios .....	34
Rizzini Maurizio Lodi .....	20	Tsiliggiris Vasileios .....	28, 34
Rogdakis Athanasios .....	35	Tzagkarakis Fragkiskos .....	35
Rousas Nikolaos .....	19	Tzilalis Vasileios .....	28
<b>S</b>		Tzirakis Konstantinos .....	18
Sachmpazidis Ioannis .....	39, 44	<b>U</b>	
Sachsamanis Georgios .....	39, 44, 48	Ugurlucan Murat .....	29, 36, 41, 43, 45, 50, 51, 53, 54
Sambalioti Athina .....	7	<b>V</b>	
Sayin Omer Ali .....	29, 45, 54	Vaiou Maria .....	8
Schwindt Arne .....	22	Vasilopoulos Ioannis .....	19
Sencer Serra .....	43	Vourliotakis Georgios .....	34
Sigala Fragiska .....	32, 46	<b>X</b>	
Spanos Konstantinos .....	6, 14, 17, 24	Xanthopoulos Dimitrios .....	30
Spiliopoulos Stavros .....	8, 12	Xenos Michalis .....	20
Spyridonidis Ioannis .....	10	<b>Z</b>	
Stamatatos Ioannis .....	35	Zarmakoupis Constantinos .....	46
Stavroulakis Konstantinos .....	16, 22	Zavalis Panagiotis .....	35
Stratakis Stavros .....	21	Zografos Georgios .....	32, 46
Stroumpos Charalampos .....	7, 31	Zoumboulidis Antonios .....	28
<b>T</b>			
Tasopoulou Kalliopi-Maria .....	49		
Tasso Paola .....	20		
Tavlas Emmanouil .....	18, 21		
Terzoglou Alexandra .....	28		
Texakalidis Pavlos .....	13		





<http://www.live2018.gr>

